

ECG Facts

made

Incredibly
Quick!™

A cartoon illustration of a woman with curly brown hair, wearing a purple top, holding a dark purple sign with yellow text. She is smiling and holding a small green plant in her left hand.

2nd
edition

Write on
Wipe off

ECG Facts

made

**Incredibly
Quick!**TM



Waterproof and Washable

*Write on the pages with a ballpoint pen.
Remove old information with an
alcohol wipe and reuse!*



Wolters Kluwer | Lippincott Williams & Wilkins
Health

Philadelphia • Baltimore • New York • London
Buenos Aires • Hong Kong • Sydney • Tokyo

Staff

Executive Publisher

Judith A. Schilling McCann, RN, MSN

Clinical Director

Joan M. Robinson, RN, MSN

Art Director

Elaine Kasmer

Editors

Margaret Eckman, Diane Labus

Illustrator

Bot Roda

Design Assistant

Kate Zulak

Associate Manufacturing Manager

Beth J. Welsh

Editorial Assistants

Karen J. Kirk, Jeri O'Shea,

Linda K. Ruhf

The clinical treatments described and recommended in this publication are based on research and consultation with nursing, medical, and legal authorities. To the best of our knowledge, these procedures reflect currently accepted practice. Nevertheless, they can't be considered absolute and universal recommendations. For individual applications, all recommendations must be considered in light of the patient's clinical condition and, before administration of new or infrequently used drugs, in light of the latest package-insert information. The authors and publisher disclaim any responsibility for any adverse effects resulting from the suggested procedures, from any undetected errors, or from the reader's misunderstanding of the text.

© 2010 by Lippincott Williams & Wilkins. All rights reserved. This book is protected by copyright. No part of it may be reproduced, stored in a retrieval system, or transmitted, in any form or by any means—electronic, mechanical, photocopy, recording, or otherwise—without prior written permission of the publisher, except for brief quotations embodied in critical articles and reviews and testing and evaluation materials provided by publisher to instructors whose schools have adopted its accompanying textbook. For information, write Lippincott Williams & Wilkins, 323 Norristown Road, Suite 200, Ambler, PA 19002-2756.

Printed in China.

ECGMIQ2-010909

ISBN-13: 978-1-60547-476-2

ISBN-10: 1-60547-476-2

Best monitoring leads

Most bedside monitoring systems allow for simultaneous monitoring of two leads, such as lead II with V_1 or MCL_1 . Lead II or the lead that clearly shows the P waves and QRS complex may be used for sinus node arrhythmias, PACs, and AV block. The precordial leads V_1 and V_6 or the bipolar leads MCL_1 and MCL_6 are the best leads for monitoring rhythms with wide QRS complexes and for differentiating VT from SVT with aberrancy.

This table lists the best leads for monitoring challenging cardiac arrhythmias.

Arrhythmia	Best monitoring leads
<i>PACs</i>	II or lead that shows best P waves
<i>AT</i>	II, V_1 , V_6 , MCL_1 , MCL_6
<i>PAT</i>	II, V_1 , V_6 , MCL_1 , MCL_6
<i>Atrial flutter</i>	II, III
<i>Atrial fibrillation</i>	II (or identified in most leads by fibrillatory waves and irregular R-R)
<i>PJCs</i>	II
<i>Junctional escape rhythm</i>	II
<i>Junctional tachycardia</i>	II, V_1 , V_6 , MCL_1 , MCL_6
<i>PVCs</i>	V_1 , V_6 , MCL_1 , MCL_6
<i>Idioventricular rhythm</i>	V_1 , V_6 , MCL_1 , MCL_6
<i>VT</i>	V_1 , V_6 , MCL_1 , MCL_6
<i>VF</i>	Any
<i>Torsades de pointes</i>	Any
<i>Third-degree AV block</i>	II or lead that shows best P waves and QRS complexes

Heart anatomy, coronary vessels, cardiac conduction, ECG grid, Einthoven's triangle, leads, normal ECG, QTc interval, interpreting rhythm strips, measuring rhythm, rhythm strip patterns, calculating HR

Sinus rhythm, sinus arrhythmia, SB, ST, sinus arrest, SA exit block, SSS

PACs, AT, MAT, PAT, atrial flutter, atrial fibrillation, Ashman's phenomenon, wandering pacemaker

PJCs, junctional rhythm, accelerated junctional rhythm, junctional tachycardia

PVCs, idioventricular rhythm, accelerated idioventricular rhythm, VT, torsades de pointes, VF, asystole, PEA

First-degree AV block, second-degree AV block, third-degree AV block

Lead placement, electrical axis, angina, pericarditis, MI, LVH, WPW, RBBB, LBBB

Algorithms, drugs, defibrillation, pacemaker, ICD

General

SA Node

Atrial

Junctional

Ventricular

AV Block

12-Lead

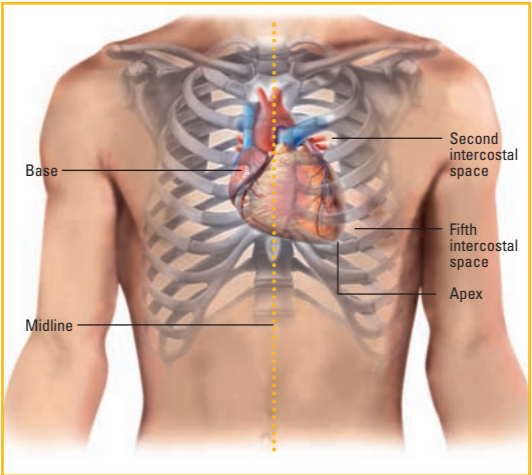
Treatment

Common abbreviations

ACLS advanced cardiac life support	MI myocardial infarction
ACS acute coronary syndromes	O₂ oxygen
AED automated external defibrillator	PA pulmonary artery
AT atrial tachycardia	PAC premature atrial contraction
AV atrioventricular	PAD pulmonary artery diastolic
BBB bundle-branch block	PAM pulmonary artery mean
BCLS basic cardiac life support	PAP pulmonary artery pressure
BP blood pressure	PAS pulmonary artery systolic
CAD coronary artery disease	PAT paroxysmal atrial tachycardia
CI cardiac index	PAWP pulmonary artery wedge pressure
CO cardiac output	PEA pulseless electrical activity
CO₂ carbon dioxide	PJC premature junctional contraction
COPD chronic obstructive pulmonary disease	PMI point of maximal impulse
CPR cardiopulmonary resuscitation	PSVT paroxysmal supraventricular tachycardia
CV cardiovascular	PVC premature ventricular contraction
DTR deep tendon reflex	RAP right arterial pressure
ECG electrocardiogram	RBBB right bundle-branch block
EF ejection fraction	SA sinoatrial
EMS emergency medical service	Sao₂ arterial blood oxygen saturation
ET endotracheal	SB sinus bradycardia
Fio₂ fraction of inspired oxygen	Spo₂ pulse oximetry blood oxygen saturation
GI gastrointestinal	SSS sick sinus syndrome
GU genitourinary	ST sinus tachycardia
HR heart rate	SV stroke volume
IABP intra-aortic balloon pump	Svo₂ mixed venous oxygen saturation
ICD implantable cardioverter- defibrillator	SVT supraventricular tachycardia
ICP intracranial pressure	VF ventricular fibrillation
ICS intercostal space	VT ventricular tachycardia
ICU intensive care unit	WPW Wolff-Parkinson-White (syndrome)
JVD jugular vein distention	
LBBB left bundle-branch block	
LVH left ventricular hypertrophy	
MAP mean arterial pressure	
MAT multifocal atrial tachycardia	
MCL modified chest lead	

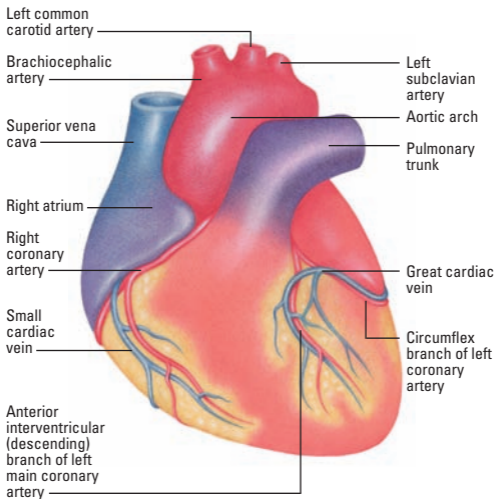
Where the heart lies

This illustration shows exactly where the heart is located. The heart lies within the mediastinum, a cavity that contains the tissues and organs separating the two pleural sacs. In most people, two-thirds of the heart extends to the left of the body's midline.



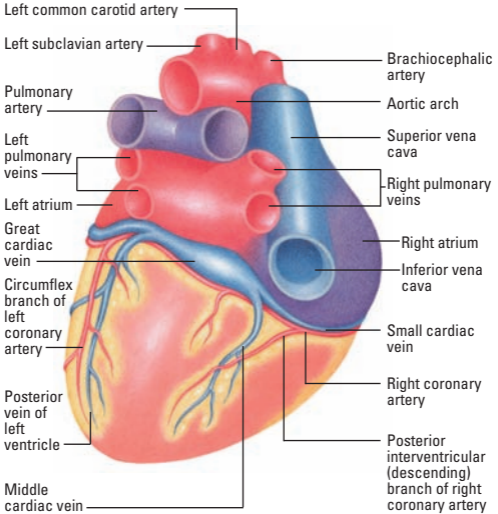
Coronary vessels

Anterior view

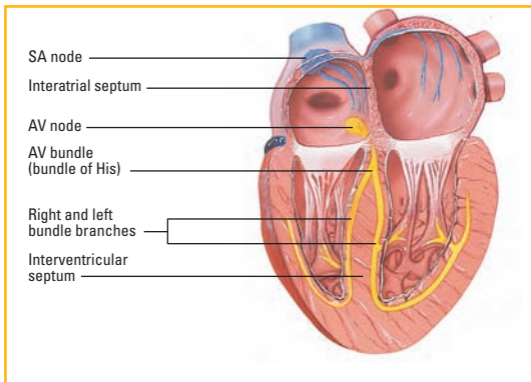


Coronary vessels (continued)

Posterior view

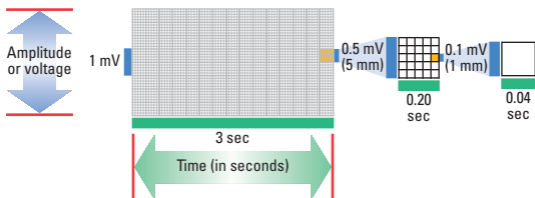


Cardiac conduction system



ECG grid

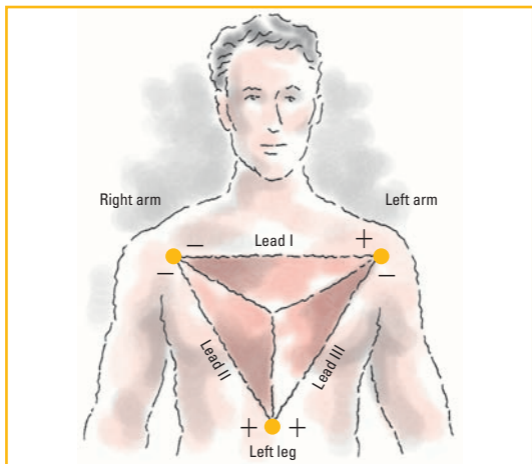
This ECG grid shows the horizontal axis and vertical axis and their respective measurement values.



Einthoven's triangle

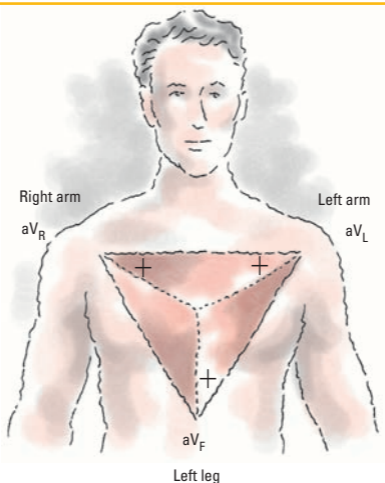
The axes of the three bipolar limb leads (I, II, and III) form a shape known as *Einthoven's triangle*. Because the electrodes for these leads are about equidistant from the heart, the triangle is equilateral.

The axis of lead I extends from shoulder to shoulder, with the right-arm lead being the negative electrode and the left-arm lead being the positive electrode. The axis of lead II runs from the negative right-arm lead electrode to the positive left-leg lead electrode. The axis of lead III extends from the negative left-arm lead electrode to the positive left-leg lead electrode.



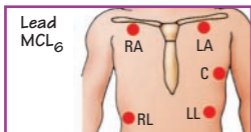
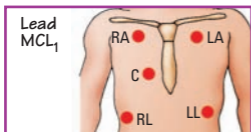
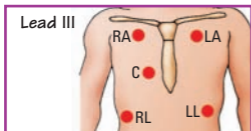
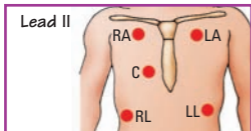
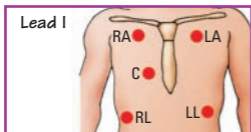
Augmented leads

Leads aV_R , aV_L , and aV_F are called *augmented leads*. They measure electrical activity between one limb and a single electrode. Lead aV_R provides no specific view of the heart. Lead aV_L shows electrical activity coming from the heart's lateral wall. Lead aV_F shows electrical activity coming from the heart's inferior wall.

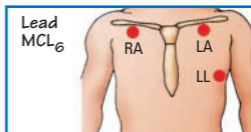
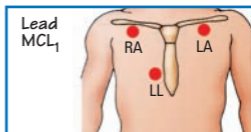
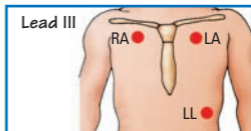
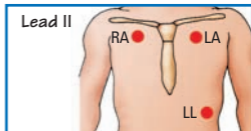
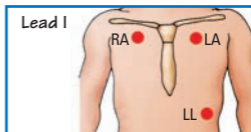


Positioning cardiac monitoring leads

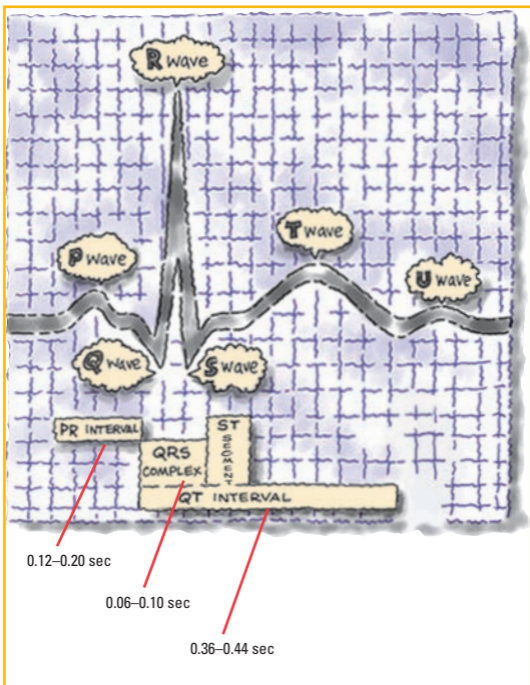
Five-leadwire system



Three-leadwire system



Normal ECG



QTc interval normals

Heart rate (per minute)	QTc interval normal range (seconds)
40	0.41 – 0.51
50	0.38 – 0.46
60	0.35 – 0.43
70	0.33 – 0.41
80	0.32 – 0.39
90	0.30 – 0.36
100	0.28 – 0.34
120	0.26 – 0.32
150	0.23 – 0.28
180	0.21 – 0.25
200	0.20 – 0.24

Interpreting rhythm strips

Interpreting a rhythm strip is a skill developed through practice. You can use several methods, as long as you're consistent. Rhythm strip analysis requires a sequential and systematic approach. The eight-step method outlined below provides just that.

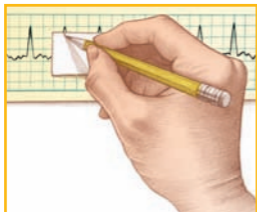Eight-step method

1. Determine the rhythm.
2. Determine the rate.
3. Evaluate the P wave.
4. Measure the PR interval.
5. Determine the QRS duration.
6. Examine the T waves.
7. Measure the QT interval.
8. Check for ectopic beats and other abnormalities.

Methods of measuring rhythm

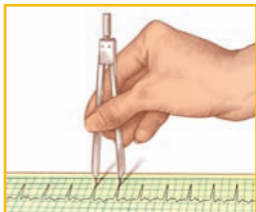
Paper-and-pencil method

- Position the straight edge of a piece of paper along the strip's baseline.
- Move the paper up slightly so the straight edge is near the peak of the R wave.
- With a pencil, mark the paper at the R waves of two consecutive QRS complexes, as shown below. This is the R-R interval.
- Move the paper across the strip lining up the two marks with succeeding R-R intervals. If the distance for each R-R interval is the same, the ventricular rhythm is regular. If the distance varies, the rhythm is irregular.
- Use the same method to measure the distance between P waves (the P-P interval) and determine whether the atrial rhythm is regular or irregular.



Calipers method

- With the ECG on a flat surface, place one point of the calipers on the peak of the first R wave of two consecutive QRS complexes.
- Adjust the calipers' legs so the other point is on the peak of the next R wave, as shown below. The distance is the R-R interval.
- Pivot the first point of the calipers toward the third R wave and note whether it falls on the peak of that wave.
- Check succeeding R-R intervals in the same way. If they're all the same, the ventricular rhythm is regular. If they vary, the rhythm is irregular.
- Using the same method, measure the P-P intervals to determine whether the atrial rhythm is regular or irregular.



Rhythm strip patterns

The more you look at rhythm strips, the more you'll notice patterns. The symbols below represent some of the patterns you might see as you study rhythm strips.

Normal, regular (as in normal sinus rhythm)



Slow, regular (as in SB)



Fast, regular (as in ST)



Premature (as in a PVC)



Grouped (as in type I second-degree AV block)



Irregularly irregular (as in atrial fibrillation)



Paroxysm or burst (as in PAT)



Calculating heart rate

This table can help make the sequencing method of determining heart rate more precise. After counting the number of blocks between R waves, use this table to find the rate. For example, if you count 20 small blocks or 4 large blocks between R waves, the heart rate is 75 beats/minute. To calculate the atrial rate, follow the same method using P waves.

Rapid estimate

This rapid-rate calculation is also called the *countdown method*. Using the number of large blocks between R waves or P waves as a guide, you can rapidly estimate ventricular or atrial rates by memorizing the sequence "300, 150, 100, 75, 60, 50."

Number of small blocks	Heart rate
5 (1 large block)	300
6	250
7	214
8	188
9	167
10 (2 large blocks)	150
11	136
12	125
13	115
14	107
15 (3 large blocks)	100
16	94
17	88
18	83
19	79
20 (4 large blocks)	75
21	71
22	68
23	65
24	63
25 (5 large blocks)	60
26	58
27	56
28	54
29	52
30 (6 large blocks)	50
31	48
32	47
33	45
34	44
35 (7 large blocks)	43
36	42
37	41
38	39
39	38
40 (8 large blocks)	37

Bradycardia and tachycardia in children

In children, evaluate bradycardia and tachycardia in context. For example, bradycardia (less than 90 beats/minute) may occur in a healthy infant during sleep; tachycardia may be a normal response when a child is crying or otherwise upset. Keep in mind that, because HR varies considerably from the neonate to the adolescent, one definition of bradycardia or tachycardia can't fit all children.

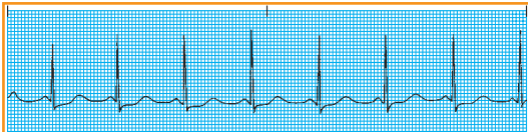
Normal heart rates in children

Age	Awake (beats/min)	Asleep (beats/min)	Exercise or fever (beats/min)
Neonate	100-160	80-140	< 220
1 wk-3 mo	100-220	80-200	< 220
3 mo-2 yr	80-150	70-120	< 200
2-10 yr	70-110	60-90	< 200
> 10 yr	55-100	50-90	< 200

ECG effects of electrolyte imbalances

Imbalance	Key finding	Other possible findings
Hypercalcemia	Shortened QT interval	<ul style="list-style-type: none"> • Prolonged PR interval • Prolonged QRS complex • Depressed T wave
Hypocalcemia	Prolonged QT interval	<ul style="list-style-type: none"> • Flat or inverted T wave • Prolonged ST segment
Hyperkalemia	Tall, peaked T waves	<ul style="list-style-type: none"> • Low amplitude P wave (mild hyperkalemia) • Wide, flattened P wave (moderate hyperkalemia) • Indiscernible P wave (severe hyperkalemia) • Widened QRS complex • Shortened QT interval • Intraventricular conduction disturbances • Elevated ST segment (severe hyperkalemia)
Hypokalemia	Flat T wave; U wave appears	<ul style="list-style-type: none"> • Peaked P wave (severe hypokalemia) • Prolonged QRS complex (severe hypokalemia) • Depressed ST segment

Normal sinus rhythm



Rhythm

- Atrial: regular
- Ventricular: regular

Rate

- 60 to 100 beats/minute (SA node's normal firing rate)

P Wave

- Normal shape (round and smooth)
- Upright in lead II
- One for every QRS complex
- All similar in size and shape

PR Interval

- Within normal limits (0.12 to 0.20 second)

QRS complex

- Within normal limits (0.06 to 0.10 second)

T wave

- Normal shape
- Upright and rounded in lead II

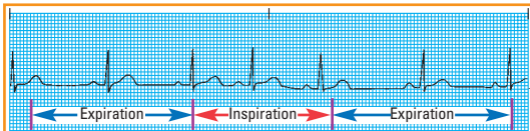
QT interval

- Within normal limits (0.36 to 0.44 second)

Other

- Represents normal cardiac conduction as the standard against which all other rhythms are compared
- No ectopic or aberrant beats

Sinus arrhythmia



Rhythm

- Irregular
- Corresponds to the respiratory cycle
- P-P interval and R-R interval shorter during inspiration; longer during expiration
- Difference between longest and shortest P-P interval exceeds 0.12 second

Rate

- Usually within normal limits (60 to 100 beats/minute)
- Varies with respiration
- Increases during inspiration
- Decreases during expiration

P wave

- Normal size
- Normal configuration

PR interval

- May vary slightly
- Within normal limits

QRS complex

- Preceded by P wave

T wave

- Normal size
- Normal configuration

QT interval

- May vary slightly
- Usually within normal limits

Other

- Phasic slowing and quickening

Sinus arrhythmia (continued)

What causes it

- Drugs
 - Digoxin
 - Morphine
- Increased ICP
- Inferior-wall MI
- Inhibition of reflex vagal activity (tone)

During inspiration

- Decreased vagal tone
- Increased HR
- Increased venous return

During expiration

- Decreased HR
- Decreased venous return
- Increased vagal tone

What to look for

- Possibly no symptoms (commonly insignificant)
- Increased peripheral pulse rate during inspiration
- Decreased peripheral pulse rate during expiration

- Possible disappearance of arrhythmia when HR increases, such as during exercise
- Signs and symptoms of underlying condition, if present
- Dizziness or syncope (with marked sinus arrhythmia)

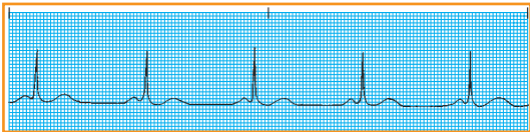
What to do

- Monitor heart rhythm.
- If sinus arrhythmia develops suddenly in patient taking digoxin, notify doctor.
- If induced by drugs (morphine or another sedative), notify doctor, who will decide whether to continue giving the drug.

How it's treated

- Usually no treatment if patient asymptomatic
- If unrelated to respiration (abnormal), treatment of underlying cause

Sinus bradycardia



Rhythm

- Regular

Rate

- Less than 60 beats/minute

P wave

- Normal size
- Normal configuration
- P wave before each QRS complex

PR interval

- Within normal limits
- Constant

QRS complex

- Normal duration
- Normal configuration

T wave

- Normal size
- Normal configuration

QT interval

- Within normal limits
- Possibly prolonged

Sinus bradycardia (continued)

What causes it

- Cardiomyopathy
- Conditions that increase vagal stimulation such as vomiting
- Drugs
 - Antiarrhythmics (amiodarone, propafenone, quinidine, sotalol)
 - Beta-adrenergic blockers (metoprolol, propranolol)
 - Calcium channel blockers (diltiazem, verapamil)
 - Digoxin
 - Lithium
- Glaucoma
- Hyperkalemia
- Hypothermia
- Hypothyroidism
- Increased ICP
- Inferior-wall MI
- Myocardial ischemia
- Myocarditis
- SA node disease

What to look for

- Pulse rate less than 60 beats/minute
- Regular rhythm
- Possibly bradycardia-induced syncope (known as a *Stokes-Adams attack*)

If patient can compensate for decreased CO

- No symptoms

If patient can't compensate

- Altered mental status
- Blurred vision
- Chest pain
- Cool, clammy skin
- Crackles
- Dizziness
- Dyspnea
- Hypotension
- S₃ heart sound, indicating heart failure
- Syncope

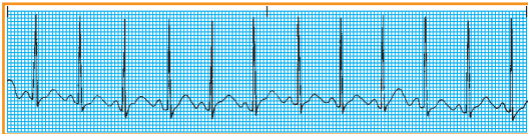
What to do

- Observe patient and monitor heart rhythm for bradycardia progression.
- Evaluate patient's tolerance for rhythm at rest and with activity.
- Prepare patient for treatments, as needed, such as drug administration (atropine, dopamine, epinephrine) or temporary or permanent pacemaker insertion.

How it's treated

- No treatment if patient asymptomatic
- If symptomatic, correction of underlying cause
- Bradycardia algorithm guidelines

Sinus tachycardia



Rhythm

- Regular

Rate

- Greater than 100 beats/minute

P wave

- Normal size
- Normal configuration
- May increase in amplitude
- Precedes each QRS complex
- As HR increases, possibly superimposed on preceding T wave and difficult to identify

PR interval

- Within normal limits
- Constant

QRS complex

- Normal duration
- Normal configuration

T wave

- Normal size
- Normal configuration

QT interval

- Within normal limits
- Commonly shortened

Sinus tachycardia (continued)

What causes it

- Anemia
- Cardiogenic shock
- Drugs
 - Aminophylline
 - Amphetamines
 - Atropine
 - Dobutamine
 - Dopamine
 - Epinephrine
 - Isoproterenol
- Heart failure
- Hemorrhage
- Hyperthyroidism
- Hypovolemia
- Pericarditis
- Pulmonary embolism
- Respiratory distress
- Sepsis
- Triggers (alcohol, caffeine, nicotine)
- Possibly normal response to exercise, fever, stress, anxiety, or pain

What to look for

- Peripheral pulse rate above 100 beats/minute
- Regular rhythm

If CO falls and compensatory mechanisms fail

- Anxiety
- Blurred vision
- Chest pain
- Hypotension
- Nervousness
- Palpitations
- Syncope

If heart failure develops

- Crackles
- S₃ heart sound
- Jugular vein distention


What to do

- Monitor heart rhythm.
- Notify doctor promptly if sinus tachycardia arises suddenly after MI.
- Provide calm environment and teach relaxation techniques.

How it's treated

- No treatment if patient asymptomatic
- Correction of underlying cause
- For cardiac ischemia: Beta-adrenergic blockers (propranolol, atenolol) or calcium channel blockers (verapamil, diltiazem)
- Abstinence from triggers (alcohol, caffeine, nicotine)

Sinus arrest



Rhythm

- Regular except during arrest (irregular as result of missing complexes)

Rate

- Usually within normal limits (60 to 100 beats/minute) before arrest
- Length or frequency of pause may result in bradycardia

P wave

- Periodically absent, with entire PQRST complexes missing
- When present, normal size and configuration
- Precedes each QRS complex

PR interval

- Within normal limits when a P wave is present
- Constant when a P wave is present

QRS complex

- Normal duration
- Normal configuration
- Absent during arrest

T wave

- Normal size
- Normal configuration
- Absent during arrest

QT interval

- Within normal limits
- Absent during arrest

Other

- The pause isn't a multiple of the underlying P-P intervals
- Junctional escape beats may occur at end of pause

Sinus arrest (continued)

What causes it

- Acute infection
- Acute inferior-wall MI
- Acute myocarditis
- CAD
- Cardioactive drugs
 - Amiodarone
 - Beta-adrenergic blockers (bisoprolol, metoprolol, propranolol)
 - Calcium channel blockers (diltiazem, verapamil)
 - Digoxin
 - Procainamide
 - Quinidine
- Cardiomyopathy
- Hypertensive heart disease
- Increased vagal tone or carotid sinus sensitivity
- Salicylate toxicity
- Sinus node disease
- SSS

What to look for

- Absence of heart sounds and pulse during arrest
- Absence of symptoms with short pauses

- Evidence of decreased CO with recurrent or prolonged pauses
 - Altered mental status
 - Blurred vision
 - Dizziness
 - Cool, clammy skin
 - Low blood pressure
 - Syncope or near-syncope

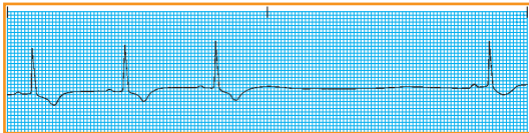
What to do

- Monitor heart rhythm.
- Protect patient from injury, such as a fall, which may result from syncopal or near-syncopal episodes caused by prolonged pause.

How it's treated

- No treatment if patient asymptomatic
- If symptoms, follow bradycardia algorithm
- As needed, discontinuation of drugs affecting SA node discharge or conduction, such as beta-adrenergic blockers, calcium channel blockers, and digoxin

Sinoatrial exit block



Rhythm

- Regular except during a pause (irregular as result of a pause)

Rate

- Usually within normal limits (60 to 100 beats/minute) before a pause
- Length or frequency of pause may result in bradycardia

P wave

- Periodically absent, with entire PQRST complex missing
- When present, normal size and configuration and precedes each QRS complex

PR interval

- Within normal limits
- Constant when a P wave is present

QRS complex

- Normal duration
- Normal configuration
- Absent during a pause

T wave

- Normal size
- Normal configuration
- Absent during a pause

QT interval

- Within normal limits
- Absent during a pause

Other

- The pause is a multiple of the underlying P-P interval

Sinoatrial exit block (continued)

What causes it

- Acute infection
- Acute inferior-wall MI
- Acute myocarditis
- Cardioactive drugs
 - Amiodarone
 - Beta-adrenergic blockers (bisoprolol, metoprolol, propranolol)
 - Calcium channel blockers (diltiazem, verapamil)
 - Digoxin
 - Procainamide
 - Quinidine
- CAD
- Cardiomyopathy
- Hypertensive heart disease
- Increased vagal tone
- Salicylate toxicity
- Sinus node disease
- SSS

What to look for

- Absence of heart sounds and pulse during SA exit block
- Absence of symptoms with short pauses

- Evidence of decreased CO with recurrent or prolonged pauses
 - Altered mental status
 - Blurred vision
 - Cool, clammy skin
 - Dizziness
 - Low blood pressure
 - Syncope or near-syncope

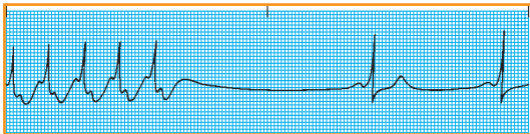
What to do

- Monitor heart rhythm.
- Protect patient from injury, such as a fall, which may result from syncopal or near-syncopal episodes caused by prolonged pause.

How it's treated

- No treatment if patient asymptomatic
- If symptomatic, guidelines for symptomatic bradycardia response
- As needed, discontinuation of drugs affecting SA node discharge or conduction, such as beta-adrenergic blockers, calcium channel blockers, and digoxin

Sick sinus syndrome



Rhythm

- Irregular
- Sinus pauses
- Abrupt rate changes

Rate

- Fast, slow, or alternating
- Interrupted by a long sinus pause

P wave

- Varies with rhythm changes
- May be normal size and configuration
- May be absent
- Usually precedes each QRS complex

PR interval

- Usually within normal limits
- Varies with rhythm changes

QRS complex

- Duration within normal limits
- Varies with rhythm changes
- Normal configuration

T wave

- Normal size
- Normal configuration

QT interval

- Usually within normal limits
- Varies with rhythm changes

Other

- Usually more than one arrhythmia on a 6-second strip

Sick sinus syndrome (continued)

What causes it

- Autonomic disturbances that affect autonomic innervation
 - Degeneration of autonomic system
 - Hypervagotonia
- Cardioactive drugs
 - Beta-adrenergic blockers
 - Calcium channel blockers
 - Digoxin
- Conditions leading to fibrosis of SA node
 - Advanced age
 - Atherosclerotic heart disease
 - Cardiomyopathy
 - Hypertension
- Inflammation of atrial wall around SA node
- Trauma to SA node
 - Open-heart surgery, especially valve surgery
 - Pericarditis
 - Rheumatic heart disease

What to look for

- Changes in heart rate and rhythm
- Episodes of tachy-brady syndrome, atrial flutter, atrial fibrillation, SA block, or sinus arrest
- Syncope (Stokes-Adams attacks)

If underlying cardiomyopathy present

- Dilated and displaced left ventricular apical impulse
- Possible crackles
- S₃ heart sound

If thromboembolism present

- Acute chest pain
- Dyspnea or tachypnea
- Fatigue
- Hypotension
- Neurologic changes (confusion, vision disturbances, weakness)

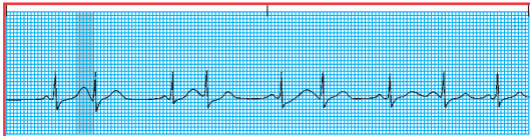
What to do

- Monitor for changes in heart rhythm.
- Prepare patient for possible treatment interventions.

How it's treated

- No treatment if patient asymptomatic
- If symptomatic, correction of underlying cause
- Insertion of temporary pacemaker (transcutaneous or transvenous)
- If arrhythmia due to chronic disorder: digoxin, beta-adrenergic blocker, radio-frequency ablation, or permanent pacemaker
- Anticoagulant for atrial fibrillation

Premature atrial contractions



Rhythm

- Atrial: Irregular
- Ventricular: Irregular
- Underlying: Possibly regular

Rate

- Atrial and ventricular: Vary with underlying rhythm

P wave

- Premature
- Abnormal configuration compared to a sinus P wave
- If varying configurations, multiple ectopic sites
- May be hidden in preceding T wave (see shaded area on strip)

PR interval

- Usually within normal limits
- May be shortened or slightly prolonged for the ectopic beat

QRS complex

- Conducted: Duration and configuration usually normal
- Nonconducted: No QRS complex follows PAC

T wave

- Usually normal
- May be distorted if P wave is hidden in T wave

QT interval

- Usually within normal limits

Other

- May be a single beat
- May be bigeminal (every other beat premature)
- May be trigeminal (every third beat premature)
- May be quadrigeminal (every fourth beat premature)
- May occur in couplets (pairs)
- Three or more PACs in a row indicate atrial tachycardia

Premature atrial contractions (continued)

What causes them

- Enhanced automaticity in atrial tissue (most common cause)
- Acute respiratory failure
- COPD
- Coronary heart disease
- Digoxin toxicity
- Drugs that prolong absolute refractory period of SA node
 - Procainamide
 - Quinidine
- Electrolyte imbalances
- Endogenous catecholamine release from pain or anxiety
- Fatigue
- Fever
- Heart failure
- Hyperthyroidism
- Hypoxia
- Infectious disease
- Triggers (alcohol, caffeine, nicotine)
- Valvular heart disease

What to look for

- Pulse rhythm and rate that reflect underlying rhythm
- Irregular peripheral or apical pulse rhythm when PACs occur
- Evidence of decreased CO, such as hypotension and syncope, if patient has heart disease

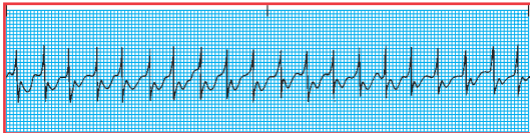
What to do

- Monitor heart rhythm.
- If patient has ischemic or valvular heart disease, watch for evidence of heart failure, electrolyte imbalances, and more severe atrial arrhythmias. *Note:* In patients with acute MI, PACs may be early signs of heart failure or an electrolyte imbalance.
- Teach patient to correct or avoid underlying causes or triggers such as caffeine.
- Demonstrate stress-reduction techniques to lessen anxiety.

How they're treated

- Usually no treatment if patient asymptomatic
- If symptomatic, elimination or control of triggers
- For frequent PACs: drugs that prolong atrial refractory period, such as beta-adrenergic blockers and calcium channel blockers

Atrial tachycardia



Rhythm

- Atrial: Usually regular
- Ventricular: Regular or irregular depending on AV conduction ratio and type of atrial tachycardia

Rate

- Atrial: Three or more consecutive ectopic atrial beats at 150 to 250 beats/minute; rarely exceeds 250 beats/minute
- Ventricular: Varies, depending on AV conduction ratio

P wave

- Deviates from normal appearance
- May be hidden in preceding T wave
- If visible, usually upright and precedes each QRS complex

PR interval

- May be difficult to measure if P wave can't be distinguished from preceding T wave

QRS complex

- Usually normal duration and configuration
- May be abnormal if impulses conducted abnormally through ventricles

T wave

- Usually visible
- May be distorted by P wave
- May be inverted if ischemia is present

QT interval

- Usually within normal limits
- May be shorter because of rapid rate

Other

- May be difficult to differentiate atrial tachycardia with block from sinus arrhythmia with U waves

Atrial tachycardia (continued)

What causes it

- Digoxin toxicity (most common)
- Cardiomyopathy
- COPD
- Congenital anomalies
- Cor pulmonale
- Drugs
 - Albuterol
 - Cocaine
 - Theophylline
- Electrolyte imbalances
- Hyperthyroidism
- Hypoxia
- MI
- Physical or psychological stress
- Systemic hypertension
- Triggers (alcohol, caffeine, nicotine)
- Valvular heart disease
- WPW syndrome

What to look for

- Rapid HR
- Sudden feeling of palpitations, especially with PAT
- Signs of decreased CO (hypotension, chest pain, syncope)

What to do

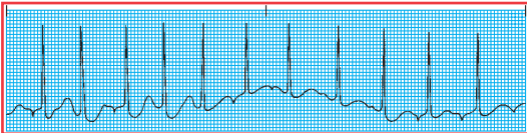
- Monitor heart rhythm.
- Assess patient for digoxin toxicity; monitor digoxin blood level.

- Keep resuscitative equipment readily available if vagal maneuvers are used.

How it's treated

- Treatment dependent on type of tachycardia and symptom severity; directed toward eliminating cause and decreasing ventricular rate
- Possibly Valsalva's maneuver or carotid sinus massage to treat PAT
- Drug therapy (pharmacologic cardioversion): adenosine, amiodarone, beta-adrenergic blockers, calcium channel blockers, digoxin
- If patient unstable, possible synchronized electrical cardioversion
- Atrial overdrive pacing
- If arrhythmia related to WPW syndrome, possible catheter ablation
- In patient with COPD, correction of hypoxia and electrolyte imbalances

Multifocal atrial tachycardia



Rhythm

- Atrial: Irregular
- Ventricular: Irregular

Rate

- Atrial: 100 to 250 beats/minute (usually less than 160 beats/minute)
- Ventricular: 100 to 250 beats/minute

P wave

- Configuration: Varies
- At least three different P wave shapes must appear

PR interval

- Varies

QRS complex

- Usually normal
- May become aberrant if arrhythmia persists

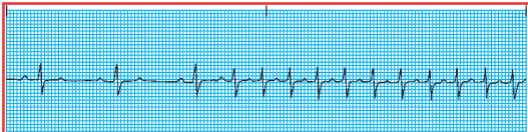
T wave

- Usually distorted

QT interval

- May be indiscernible

Paroxysmal atrial tachycardia



Rhythm

- Atrial: Regular
- Ventricular: Regular

Rate

- Atrial: 150 to 250 beats/minute
- Ventricular: 150 to 250 beats/minute

P wave

- May not be visible
- May be difficult to distinguish from preceding T wave

PR interval

- May not be measurable if P wave can't be distinguished from preceding T wave

QRS complex

- Usually normal; may be aberrantly conducted

T wave

- Usually indistinguishable

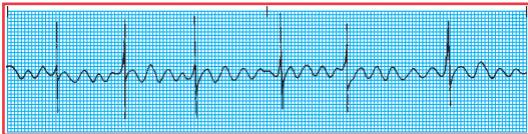
QT interval

- May be indistinguishable

Other

- Sudden onset, typically started by PAC; may start and stop abruptly

Atrial flutter



Rhythm

- Atrial: Regular
- Ventricular: Typically regular, although cycles may alternate (depends on AV conduction pattern)

Rate

- Atrial: 250 to 400 beats/minute
- Ventricular: Usually 60 to 150 beats/minute (one-half to one-fourth of atrial rate), depending on degree of AV block
- Usually expressed as a ratio (2:1 or 4:1, for example)
- Commonly 300 beats/minute atrial and 150 beats/minute ventricular; known as *2:1 block*
- Only every second, third, or fourth impulse is conducted to ventricles because the AV node usually won't accept more than 180 impulses/minute
- When atrial flutter is first recognized, ventricular rate typically exceeds 100 beats/minute

P wave

- Abnormal
- Sawtoothed appearance known as *flutter waves* or *F waves*

PR interval

- Not measurable

QRS complex

- Duration: Usually within normal limits
- May be widened if flutter waves are buried within the complex

T wave

- Not identifiable

QT interval

- Not measurable because T wave isn't identifiable

Other

- Atrial rhythm may vary between a fibrillatory line and flutter waves (called *atrial fib-flutter*), with an irregular ventricular response
- May be difficult to differentiate atrial flutter from atrial fibrillation

Atrial flutter (continued)

What causes it

- Cardiac surgery with acute MI
- Conditions that enlarge atrial tissue and elevate atrial pressures
- COPD
- Digoxin toxicity
- Hyperthyroidism
- MI
- Mitral or tricuspid valve disease
- Pericardial disease
- Systemic arterial hypoxia

What to look for

- Possibly no symptoms if ventricular rate is normal
- Rapid HR if ventricular rate is rapid (complaint of palpitations)
- Evidence of reduced CO if ventricular rate is rapid
- Evidence of reduced ventricular filling time and coronary perfusion from rapid ventricular rate
 - Angina
 - Heart failure
 - Hypotension
 - Pulmonary edema
 - Syncope

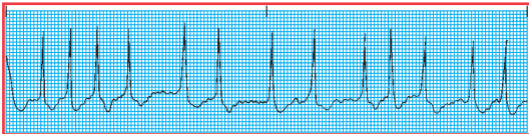
What to do

- Monitor heart rhythm.
- Keep resuscitative equipment at bedside; be alert for bradycardia because cardioversion can decrease HR.
- Be alert for effects of digoxin, which depresses SA node.
- Monitor patient closely for evidence of low CO.

How it's treated

- If patient hemodynamically unstable and with atrial flutter of 48 hours or less, immediate synchronized electrical cardioversion
- With atrial flutter of more than 48 hours, anticoagulation therapy before and after cardioversion
- With normal heart function: beta-adrenergic blockers, such as metoprolol, or calcium channel blockers such as diltiazem
- With impaired heart function (heart failure or EF below 40%): digoxin or amiodarone
- Ablation therapy for recurrent atrial flutter

Atrial fibrillation



Rhythm

- Atrial: Irregularly irregular
- Ventricular: Irregularly irregular

Rate

- Atrial: Almost indiscernible, usually above 400 beats/minute; far exceeds ventricular rate because most impulses aren't conducted through the AV junction
- Ventricular: Usually 100 to 150 beats/minute but can be below 100 beats/minute

P wave

- Absent
- Replaced by baseline fibrillatory waves that represent atrial tetanization from rapid atrial depolarizations

PR interval

- Indiscernible

QRS complex

- Duration and configuration usually normal

T wave

- Indiscernible

QT interval

- Not measurable

Other

- Atrial rhythm may vary between fibrillatory line and flutter waves (called *atrial fib-flutter*)
- May be difficult to differentiate atrial fibrillation from atrial flutter and MAT

Atrial fibrillation (continued)

What causes it

- Acute MI
- Atrial septal defect
- CAD
- Cardiac surgery
- Cardiomyopathy
- COPD
- Digoxin toxicity
- Drugs such as aminophylline
- Endogenous catecholamine released during exercise
- Hypertension
- Hyperthyroidism
- Pericarditis
- Rheumatic heart disease
- Triggers (alcohol, caffeine, nicotine)
- Valvular heart disease (especially mitral valve disease)

What to look for

- Irregularly irregular pulse rhythm with normal or abnormal HR
- Radial pulse rate that's slower than apical pulse rate
- Evidence of decreased CO (lightheadedness, hypotension)
- Possibly no symptoms with chronic atrial fibrillation

What to do

- Monitor heart rhythm.
- Monitor for evidence of decreased cardiac output and heart failure. If patient isn't on

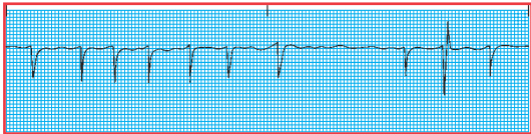
cardiac monitor, be alert for irregular pulse and differences in radial and apical pulse rates.

- If drug therapy is used, monitor serum drug levels; watch for evidence of toxicity.
- Tell patient to report changes in pulse rate, dizziness, faintness, chest pain, and signs of heart failure, such as dyspnea and peripheral edema.

How it's treated

- Drug therapy to control ventricular response, or electrical cardioversion with drug therapy
- If patient hemodynamically unstable, immediate synchronized cardioversion (most successful if done within 48 hours after atrial fibrillation onset)
- With atrial fibrillation of more than 48 hours: anticoagulation before and after cardioversion
- With otherwise normal heart function: beta-adrenergic blockers, such as metoprolol, or calcium channel blockers such as diltiazem
- With impaired heart function (heart failure or EF below 40%): digoxin or amiodarone
- Radio-frequency ablation therapy for unresponsive symptomatic atrial fibrillation

Ashman's phenomenon



Rhythm

- Atrial: Irregular
- Ventricular: Irregular

Rate

- Reflects the underlying rhythm

P wave

- May be visible
- Abnormal configuration
- Unchanged if present in the underlying rhythm

PR interval

- Commonly changes on the premature beat, if measurable at all

QRS complex

- Altered configuration with RBBB pattern

T wave

- Deflection opposite that of QRS complex in most leads because of RBBB

QT interval

- Usually changed because of RBBB

Other

- No compensatory pause after an aberrant beat
- Aberrancy may continue for several beats and typically ends a short cycle preceded by a long cycle

Ashman's phenomenon *(continued)*

What causes it

- Prolonged refractory period in slower rhythm
- Short cycle followed by long cycle because refractory period varies with length of cycle

What to look for

- No signs or symptoms

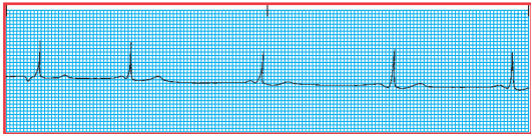
What to do

- Monitor heart rhythm.

How it's treated

- No interventions needed, but may be needed for accompanying arrhythmias

Wandering pacemaker



Rhythm

- Atrial: Varies slightly, with an irregular P-P interval
- Ventricular: Varies slightly, with an irregular R-R interval

Rate

- Varies, but usually within normal limits or less than 60 beats/minute

P wave

- Altered size and configuration from changing pacemaker site with at least three different P-wave shapes visible
- May be absent or inverted or occur after QRS complex if impulse originates in the AV junction

PR interval

- Varies from beat to beat as pacemaker site changes
- Usually less than 0.20 second
- Less than 0.12 second if the impulse originates in the AV junction

QRS complex

- Duration and configuration usually normal because ventricular depolarization is normal

T wave

- Normal size and configuration

QT interval

- Usually within normal limits

Other

- May be difficult to differentiate wandering pacemaker from PACs

Wandering pacemaker *(continued)*

What causes it

- COPD
- Digoxin toxicity
- Increased parasympathetic (vagal) influences on SA node or AV junction
- Inflammation of atrial tissue
- Valvular heart disease

What to look for

- Usually no symptoms (patient is unaware of arrhythmia)
- Pulse rate normal or less than 60 beats/minute
- Rhythm regular or slightly irregular
- At least three distinct P wave configurations (distinguish wandering pacemaker from PACs)

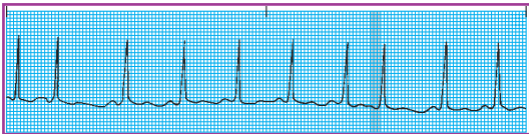
What to do

- Monitor heart rhythm.
- Watch for evidence of hemodynamic instability, such as hypotension and changes in mental status.

How it's treated

- Usually no treatment if patient asymptomatic
- If symptomatic, review of medication regimen; investigation and treatment of underlying cause of arrhythmia

Premature junctional contractions



Rhythm

- Atrial: Irregular during PJC
- Ventricular: Irregular during PJC
- Underlying rhythm possibly regular

Rate

- Atrial: Reflects underlying rhythm
- Ventricular: Reflects underlying rhythm

P wave

- Usually inverted (leads II, III, and aV_F) (see shaded area on strip)
- May occur before, during, or after QRS complex, depending on initial direction of depolarization
- May be hidden in QRS complex

PR interval

- Shortened (less than 0.12 second) if P wave precedes QRS complex
- Not measurable if no P wave precedes QRS complex

QRS complex

- Usually normal configuration and duration because ventricles usually depolarize normally

T wave

- Usually normal configuration

QT interval

- Usually within normal limits

Other

- Commonly accompanied by a compensatory pause reflecting retrograde atrial conduction

Premature junctional contractions *(continued)*

What causes them

- CAD
- COPD
- Digoxin toxicity
- Electrolyte imbalances
- Heart failure
- Hyperthyroidism
- Inferior-wall MI
- Inflammatory changes in the AV junction after heart surgery
- Myocardial ischemia
- Pericarditis
- Stress
- Triggers (alcohol, caffeine, nicotine)
- Valvular heart disease

What to look for

- Usually no symptoms
- Possible feeling of palpitations or skipped beats
- Hypotension if PJs are frequent enough

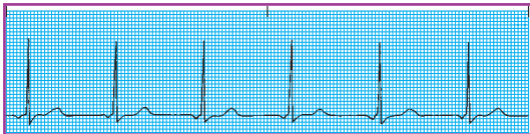
What to do

- Monitor cardiac rhythm for frequent PJs; may indicate junctional irritability and can lead to more serious arrhythmia such as junctional tachycardia.
- Monitor patient for hemodynamic instability.

How they're treated

- Usually no treatment if patient asymptomatic
- If symptomatic, treatment of underlying cause
- If digoxin toxicity, discontinuation of drug
- If ectopic beats frequent because of caffeine, decrease in or elimination of caffeine intake

Junctional rhythm



Rhythm

- Atrial: Regular
- Ventricular: Regular

Rate

- Atrial: 40 to 60 beats/minute
- Ventricular: 40 to 60 beats/minute

P wave

- Usually inverted (leads II, III, and aV_F)
- May occur before, during, or after QRS complex
- May be hidden in QRS complex

PR interval

- Shortened (less than 0.12 second) if P wave precedes QRS complex
- Not measurable if no P wave precedes QRS complex

QRS complex

- Duration: Usually within normal limits
- Configuration: Usually normal

T wave

- Configuration: Usually normal

QT interval

- Usually within normal limits

Other

- Important to differentiate junctional rhythm from idioventricular rhythm (a life-threatening arrhythmia)

Junctional rhythm *(continued)*

What causes it

- Cardiomyopathy
- Conditions that disturb normal SA node function or impulse conduction
- Drugs
 - Beta-adrenergic blockers
 - Calcium channel blockers
 - Digoxin
- Electrolyte imbalances
- Heart failure
- Hypoxia
- Increased parasympathetic (vagal) tone
- Myocarditis
- SA node ischemia
- SSS
- Valvular heart disease

What to look for

- Possibly no symptoms
- Signs of decreased CO (hypotension, syncope, blurred vision)

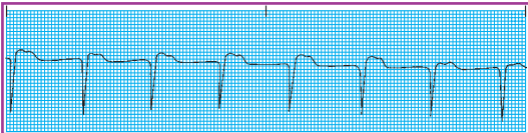
What to do

- Monitor heart rhythm.
- Monitor digoxin and electrolyte levels.
- Watch for evidence of decreased CO.

How it's treated

- Identification and correction of underlying cause
- Atropine; temporary or permanent pacemaker
- Junctional rhythm can prevent ventricular standstill; should never be suppressed

Accelerated junctional rhythm



Rhythm

- Atrial: Regular
- Ventricular: Regular

Rate

- Atrial: 60 to 100 beats/minute
- Ventricular: 60 to 100 beats/minute

P wave

- If present, inverted in leads II, III, and aV_F
- May occur before, during, or after QRS complex
- May be hidden in QRS complex

PR interval

- Shortened (less than 0.12 second) if P wave precedes QRS complex
- Not measurable if no P wave precedes QRS complex

QRS complex

- Duration: Usually within normal limits
- Configuration: Usually normal

T wave

- Usually within normal limits

QT interval

- Usually within normal limits

Other

- Need to differentiate accelerated junctional rhythm from accelerated idioventricular rhythm (a possibly life-threatening arrhythmia)

Accelerated junctional rhythm (continued)

What causes it

- Digoxin toxicity (common cause)
- Cardiac surgery
- Electrolyte disturbances
- Heart failure
- Inferior-wall MI
- Myocarditis
- Posterior-wall MI
- Rheumatic heart disease
- Valvular heart disease

What to look for

- Normal pulse rate and regular rhythm
- Possibly no symptoms
- Possibly symptoms of decreased CO (from loss of atrial kick), such as hypotension, changes in mental status, weak peripheral pulses

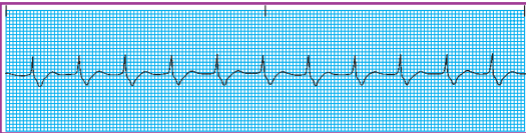
What to do

- Monitor heart rhythm.
- Watch for evidence of decreased CO and hemodynamic instability.
- Monitor serum digoxin and electrolyte levels.

How it's treated

- Identification and correction of underlying cause
- Discontinuation of digoxin

Junctional tachycardia



Rhythm

- Atrial: Usually regular but may be difficult to determine if P wave is hidden in QRS complex or preceding T wave
- Ventricular: Usually regular

Rate

- Atrial: Exceeds 100 beats/minute (usually 100 to 200 beats/minute) but may be difficult to determine if P wave isn't visible
- Ventricular: Exceeds 100 beats/minute (usually 100 to 200 beats/minute)

P wave

- Usually inverted in leads II, III, and aV_F
- May occur before, during, or after QRS complex
- May be hidden in QRS complex

PR interval

- Shortened (less than 0.12 second) if P wave precedes QRS complex
- Not measurable if no P wave precedes QRS complex

QRS complex

- Duration: Within normal limits
- Configuration: Usually normal

T wave

- Configuration: Usually normal
- May be abnormal if P wave is hidden in T wave
- May be indiscernible because of fast rate

QT interval

- Usually within normal limits

Other

- May have gradual (non-paroxysmal) or sudden (paroxysmal) onset

Junctional tachycardia *(continued)*

What causes it

- Digoxin toxicity (most common)
- Electrolyte imbalances
- Heart failure
- Hypokalemia (may aggravate condition)
- Inferior-wall MI
- Inferior-wall myocardial ischemia
- Inflammation of AV junction after heart surgery
- Posterior-wall MI
- Posterior-wall myocardial ischemia
- Valvular heart disease

What to look for

- Pulse rate above 100 beats/minute with regular rhythm
- Effects of decreased CO (loss of atrial kick) and hemodynamic instability (hypotension) because of rapid HR

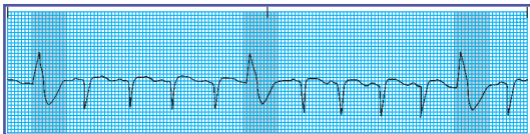
What to do

- Monitor heart rhythm.
- Watch for evidence of digoxin toxicity; monitor digoxin blood level.

How it's treated

- Identification and treatment of underlying cause
- If due to digoxin toxicity, discontinuation of digoxin; in some cases, possibly digoxin-binding drug to reduce serum digoxin level
- For recurrent junctional tachycardia, possibly ablation therapy followed by permanent pacemaker insertion
- If symptomatic with paroxysmal onset of junctional tachycardia:
 - vagal maneuvers and drugs such as adenosine to slow HR
 - with otherwise normal heart function: beta-adrenergic blockers, calcium channel blockers, or amiodarone
 - with impaired heart function (heart failure or EF below 40%): amiodarone

Premature ventricular contractions



Rhythm

- Atrial: Irregular during PVCs
- Ventricular: Irregular during PVCs
- Underlying rhythm may be regular

Rate

- Atrial: Reflects underlying rhythm
- Ventricular: Reflects underlying rhythm

P wave

- Usually absent in ectopic beat
- May appear after QRS complex with retrograde conduction to atria
- Usually normal if present in underlying rhythm

PR interval

- Not measurable except in underlying rhythm

QRS complex

- Occurs earlier than expected
- Duration: Exceeds 0.12 second

- Configuration: Bizarre and wide but usually normal in underlying rhythm (see shaded areas on strip)

T wave

- Opposite direction to QRS complex
- May trigger more serious rhythm disturbances when PVC occurs on the downslope of the preceding normal T wave (R-on-T phenomenon)

QT interval

- Not usually measured except in underlying rhythm

Other

- PVC may be followed by full or incomplete compensatory pause
- Interpolated PVC: Occurs between two normally conducted QRS complexes without great disturbance to underlying rhythm
- Full compensatory pause absent with interpolated PVCs

Premature ventricular contractions *(continued)*

What causes them

- Enhanced automaticity (usual cause)
- Drug intoxication (amphetamines, cocaine, digoxin, phenothiazines, tricyclic antidepressants)
- Electrolyte imbalances (hyperkalemia, hypocalcemia, hypomagnesemia, hypokalemia)
- Enlargement of ventricular chambers
- Hypoxia
- Increased sympathetic stimulation
- Irritable focus
- Irritation of ventricles by pacemaker electrodes or PA catheter
- Metabolic acidosis
- MI
- Mitral valve prolapse
- Myocardial ischemia
- Myocarditis
- Sympathomimetic drugs such as epinephrine
- Triggers (alcohol, caffeine, nicotine)

What to look for

- Possibly no symptoms
- Normal pulse rate with momentarily irregular pulse rhythm when PVC occurs
- Abnormally early heart sound with each PVC on auscultation

- Palpitations if PVCs are frequent
- Evidence of decreased CO (hypotension, syncope)

What to do

- Promptly assess patients with recently developed PVCs, especially those with underlying heart disease or complex medical problems.
- Monitor heart rhythm of patients with PVCs and serious symptoms.
- Observe closely for development of more frequent PVCs or more dangerous PVC patterns.
- Teach family members how to activate EMS and perform CPR if the patient will be taking antiarrhythmic drugs after discharge.

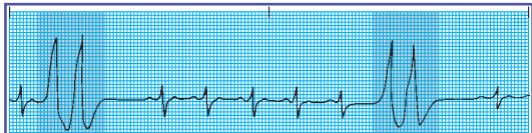
How they're treated

- No treatment if patient asymptomatic and has no evidence of heart disease
- If symptomatic, or dangerous form of PVC occurs, treatment dependent on cause
- For PVCs of purely cardiac origin: drugs to suppress ventricular irritability, such as amiodarone, lidocaine, procainamide
- For PVCs of noncardiac origin: treatment of cause

Patterns of potentially dangerous PVCs

Some PVCs are more dangerous than others. Here are some potentially dangerous ones.

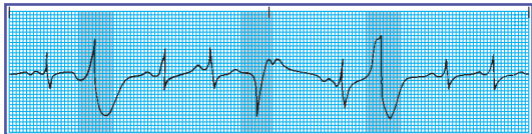
Paired PVCs



Two PVCs in a row, called *paired PVCs* or a *ventricular couplet* (see shaded areas on strip above), can produce VT because the second contrac-

tion usually meets refractory tissue. A burst, or *salvo*, of three or more PVCs in a row is considered a run of VT.

Multiform PVCs

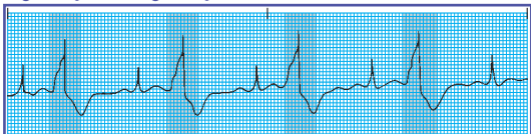


Multiform PVCs look different from one another (see shaded areas on strip above) and arise either from different sites or

from the same site via abnormal conduction. Multiform PVCs may indicate severe heart disease or digoxin toxicity.

Patterns of potentially dangerous PVCs (continued)

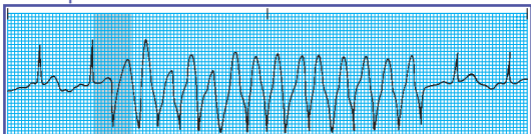
Bigeminy and trigeminy



PVCs that occur every other beat (bigeminy) or every third beat (trigeminy) can result in

VT or VF. The shaded areas on the strip shown above illustrate ventricular bigeminy.

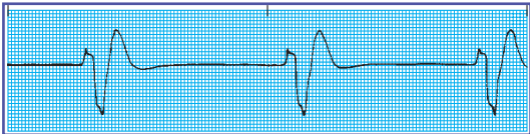
R-on-T phenomenon



In R-on-T phenomenon, a PVC occurs so early that it falls on the T wave of the preceding beat (see shaded

area on strip above). Because the cells haven't fully repolarized, VT or VF can result.

Idioventricular rhythm



Rhythm

- Atrial: Usually can't be determined
- Ventricular: Usually regular

Rate

- Atrial: Usually can't be determined
- Ventricular: 20 to 40 beats/minute

P wave

- Usually absent

PR interval

- Not measurable because of absent P wave

QRS complex

- Duration: Exceeds 0.12 second because of abnormal ventricular depolarization
- Configuration: Wide and bizarre

T wave

- Abnormal
- Usually deflects in opposite direction from QRS complex

QT interval

- Usually prolonged

Other

- Commonly occurs with third-degree AV block
- If any P waves present, not associated with QRS complex

Idioventricular rhythm *(continued)*

What causes it

- Digoxin toxicity
- Drugs
 - Beta-adrenergic blockers
 - Calcium channel blockers
 - Tricyclic antidepressants
- Failure of all of heart's higher pacemakers
- Failure of supraventricular impulses to reach ventricles because of block in conduction system
- Metabolic imbalance
- MI
- Myocardial ischemia
- Pacemaker failure
- SSS
- Third-degree AV block

What to look for

- Evidence of sharply decreased CO (hypotension, dizziness, feeling of faintness, syncope, light-headedness)
- Difficult auscultation or palpation of BP

What to do

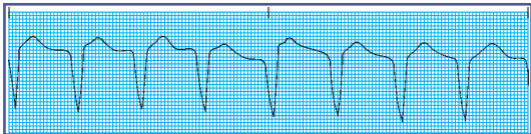
- Monitor ECG continually; periodically assess patient until hemodynamic stability has been restored.
- Keep atropine and pacemaker equipment readily available.

- Enforce bed rest until effective HR has been maintained and patient is stable.
- Tell patient and family about the serious nature of this arrhythmia and required treatment.
- If patient needs a permanent pacemaker, explain how it works, how to recognize problems, when to contact doctor, and how pacemaker function will be monitored.

How it's treated

- Suppression of arrhythmia not goal of treatment; arrhythmia acts as safety mechanism against ventricular standstill
- Possible atropine to increase HR
- In emergency, transcutaneous pacemaker until transvenous pacemaker can be inserted
- Permanent pacemaker
- Antiarrhythmic drugs (such as amiodarone, lidocaine) contraindicated for idioventricular rhythm because of possible suppression of escape beats

Accelerated idioventricular rhythm



Rhythm

- Atrial: Can't be determined
- Ventricular: Usually regular

Rate

- Atrial: Usually can't be determined
- Ventricular: 40 to 100 beats/minute

P wave

- Usually absent

PR interval

- Not measurable

QRS complex

- Duration: Exceeds 0.12 second
- Configuration: Wide and bizarre

T wave

- Abnormal
- Usually deflects in opposite direction from QRS complex

QT interval

- Usually prolonged

Other

- If any P waves present, not associated with QRS complex

Accelerated idioventricular rhythm (continued)

What causes it

- Digoxin toxicity
- Drugs
 - Beta-adrenergic blockers
 - Calcium channel blockers
 - Tricyclic antidepressants
- Failure of all of heart's higher pacemakers
- Failure of supraventricular impulses to reach ventricles because of block in conduction system
- Metabolic imbalance
- MI
- Myocardial ischemia
- Pacemaker failure
- SSS
- Third-degree AV block

What to look for

- Evidence of sharply decreased CO (hypotension, dizziness, light-headedness, syncope)
- Difficult auscultation or palpation of BP

What to do

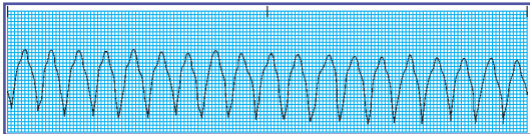
- Monitor ECG continually; periodically assess patient until hemodynamic stability has been restored.
- Keep atropine and pacemaker equipment readily available.

- Enforce bed rest until effective HR has been maintained and patient is stable.
- Tell patient and family about the serious nature of this arrhythmia and required treatment.
- If patient needs permanent pacemaker, explain how it works, how to recognize problems, when to contact physician, and how pacemaker function will be monitored.

How it's treated

- Suppression of arrhythmia not goal of treatment; arrhythmia acts as safety mechanism against ventricular standstill
- Possible atropine to increase HR
- In emergency, transcutaneous pacemaker until transvenous pacemaker can be inserted
- Permanent pacemaker
- Antiarrhythmic drugs (such as amiodarone, lidocaine) contraindicated for accelerated idioventricular rhythm because of possible suppression of escape beats

Ventricular tachycardia



Rhythm

- Atrial: Can't be determined
- Ventricular: Usually regular but may be slightly irregular

Rate

- Atrial: Can't be determined
- Ventricular: Usually rapid (100 to 250 beats/minute)

P wave

- Usually absent
- If present, not associated with QRS complex

PR interval

- Not measurable

QRS complex

- Duration: Exceeds 0.12 second
- Configuration: Usually bizarre, with increased amplitude
- Uniform in monomorphic VT
- Constantly changes shape in polymorphic VT

T wave

- If visible, occurs opposite the QRS complex

QT interval

- Not measurable

Other

- Ventricular flutter: A variation of VT

Ventricular tachycardia *(continued)*

What causes it

- Usually increased myocardial irritability, which may be triggered by:
 - enhanced automaticity
 - PVCs during downstroke of preceding T wave
 - reentry in Purkinje system
- CAD
- Cardiomyopathy
- Drug toxicity (cocaine, procainamide, or quinidine)
- Electrolyte imbalances such as hypokalemia
- Heart failure
- MI
- Myocardial ischemia
- Rewarming during hypothermia
- Valvular heart disease

What to look for

- Possibly only minor symptoms initially
- Usually weak or absent pulses
- Hypotension and decreased level of consciousness, quickly leading to unresponsiveness if untreated
- Possible angina, heart failure, and substantial decrease in organ perfusion

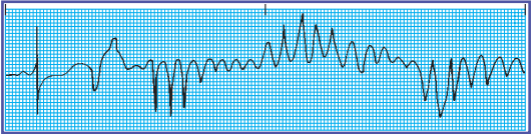
What to do

- Determine whether patient is conscious and has spontaneous respirations and palpable carotid pulse.
- Monitor heart rhythm; rhythm may rapidly progress to VF.
- Teach family members how to activate EMS and perform CPR if patient will have an ICD or be on long-term antiarrhythmic therapy after discharge.
- Teach patient and family about the serious nature of arrhythmia and need for prompt treatment.

How it's treated

- For pulseless VT, cardiopulmonary resuscitation and immediate defibrillation
- For unstable patient with pulse, immediate synchronized cardioversion
- If no definitive diagnosis of SVT or VT, amiodarone and elective synchronized cardioversion
- For stable patient with recurrent polymorphic VT, consultation with an expert
- Correction of electrolyte imbalances
- ICD

Torsades de pointes



Rhythm

- Atrial: Can't be determined
- Ventricular: May be regular or irregular

Rate

- Atrial: Can't be determined
- Ventricular: 150 to 300 beats/minute

P wave

- Not identifiable

PR interval

- Not measurable

QRS complex

- Usually wide
- Usually a phasic variation in electrical polarity, with complexes that point downward for several beats and then upward for several beats

T wave

- Not discernible

QT interval

- Prolonged

Other

- May be paroxysmal, starting and stopping suddenly

Torsades de pointes (continued)

What causes it

- AV block
- Drug toxicity (sotalol, procainamide, quinidine)
- Electrolyte imbalances (hypocalcemia, hypokalemia, hypomagnesemia)
- Hereditary QT prolongation syndrome
- Myocardial ischemia
- Prinzmetal's angina
- Psychotropic drugs (phenothiazines, tricyclic antidepressants)
- SA node disease resulting in severe bradycardia

What to look for

- Palpitations, dizziness, chest pain, and shortness of breath if patient is conscious
- Hypotension and decreased level of consciousness
- Loss of consciousness, pulse, and respirations

What to do

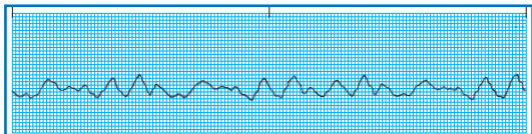
- Monitor heart rhythm and observe for QT prolongation in patients receiving drugs that may cause torsades de pointes.
- Determine whether patient is conscious and has spontaneous respirations and palpable carotid pulse.

How it's treated

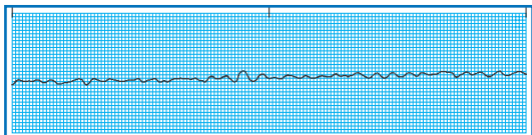
- Cardiopulmonary resuscitation
- Defibrillation
- Overdrive pacing
- Magnesium sulfate I.V.
- Discontinuation of offending drug
- Correction of electrolyte imbalances
- For unstable patient with pulse, immediate synchronized cardioversion
- ICD

Ventricular fibrillation

Coarse



Fine



Rhythm

- Atrial: Can't be determined
- Ventricular: No pattern or regularity, just fibrillatory waves

Rate

- Atrial: Can't be determined
- Ventricular: Can't be determined

P wave

- Can't be determined

PR interval

- Can't be determined

QRS complex

- Can't be determined

T wave

- Can't be determined

QT interval

- Not measurable

Other

- Electrical defibrillation more successful with coarse fibrillatory waves than with fine waves

Ventricular fibrillation *(continued)*

What causes it

- Acid-base imbalance
- CAD
- Drug toxicity (digoxin, procainamide, quinidine)
- Electric shock
- Electrolyte imbalances (hypercalcemia, hyperkalemia, hypokalemia)
- MI
- Myocardial ischemia
- Severe hypothermia
- Underlying heart disease such as dilated cardiomyopathy
- Untreated VT

What to look for

- Full cardiac arrest
- Unresponsive patient with no detectable BP or central pulses

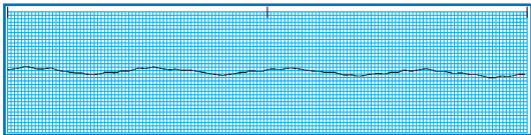
What to do

- Assess patient to determine if rhythm is VF.
- Start CPR.
- Teach patient's family about the serious nature of this arrhythmia and how to activate EMS and perform CPR.
- Teach patient and family about the ICD if applicable or antiarrhythmic therapy the patient will be taking after discharge.

How it's treated

- Cardiopulmonary resuscitation
- Immediate defibrillation: biphasic (120 to 200 joules), monophasic (360 joules)
- Epinephrine or vasopressin
- Following pulseless arrest algorithm guidelines

Asystole



Rhythm

- Atrial: Usually indiscernible
- Ventricular: Not present

Rate

- Atrial: Usually indiscernible
- Ventricular: Not present

P wave

- May be present

PR interval

- Not measurable

QRS complex

- Absent or occasional escape beats

T wave

- Absent

QT interval

- Not measurable

Other

- Looks like a nearly flat line on a rhythm strip except during chest compressions with CPR
- If the patient has a pacemaker, pacer spikes may show on the strip, but no P wave or QRS complex occurs in response

Asystole (continued)

What causes it

- Cardiac tamponade
- Drug overdose
- Hypothermia
- Hypovolemia
- Hypoxia
- Massive pulmonary embolism
- MI
- Severe electrolyte disturbances, especially hyperkalemia and hypokalemia
- Severe, uncorrected acid-base disturbances, especially metabolic acidosis
- Tension pneumothorax

What to look for

- Unresponsive patient
- Lack of spontaneous respirations, discernible pulse, and BP
- No CO or perfusion of vital organs

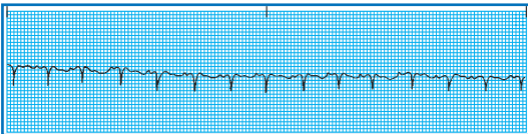
What to do

- Verify lack of do-not-resuscitate order.
- Verify asystole by checking more than one ECG lead.
- Start CPR, supplemental oxygen, and advanced airway control with tracheal intubation.

How it's treated

- Cardiopulmonary resuscitation
- Identification and rapid treatment of potentially reversible causes; otherwise, asystole possibly irreversible
- Early transcutaneous pacing
- I.V. vasopressin, epinephrine, and atropine
- For persistent asystole despite appropriate management: possible end of resuscitation

Pulseless electrical activity



Rhythm

- Atrial: Same as underlying rhythm; becomes irregular as rate slows
- Ventricular: Same as underlying rhythm; becomes irregular as rate slows

Rate

- Atrial: Reflects underlying rhythm
- Ventricular: Reflects underlying rhythm; eventually decreases

P wave

- Same as underlying rhythm; gradually flattens and then disappears

PR interval

- Same as underlying rhythm; eventually disappears as P wave disappears

QRS complex

- Same as underlying rhythm; becomes progressively wider

T wave

- Same as underlying rhythm; eventually becomes indiscernible

QT interval

- Same as underlying rhythm; eventually becomes indiscernible

Other

- Also known as *PEA*
- Characterized by some electrical activity (may be any rhythm) but no mechanical activity or detectable pulse
- Usually becomes a flat line indicating asystole within several minutes

Pulseless electrical activity *(continued)*

What causes it

- Acidosis
- Cardiac tamponade
- Drug overdoses (such as tricyclic antidepressants)
- Hyperkalemia
- Hypokalemia
- Hypothermia
- Hypovolemia
- Hypoxia
- Massive acute MI
- Massive pulmonary embolism
- Tension pneumothorax

What to look for

- Apnea and sudden loss of consciousness
- Lack of BP and pulse
- No CO or perfusion of vital organs

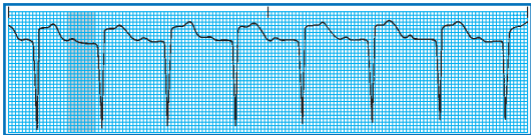
What to do

- Start CPR immediately.

How it's treated

- Cardiopulmonary resuscitation
- Epinephrine, vasopressin, and atropine according to ACLS guidelines
- Identification and treatment of cause including:
 - pericardiocentesis for cardiac tamponade
 - volume infusion for hypovolemia from hemorrhage
 - correction of electrolyte imbalances
 - ventilation for hypoxemia
 - surgery or thrombolytic therapy for massive pulmonary embolism
 - needle decompression or chest tube insertion for tension pneumothorax
- Pacemaker therapy (rarely effective)

First-degree AV block



Rhythm

- Regular

Rate

- Within normal limits or bradycardic
- Atrial the same as ventricular

P wave

- Normal size
- Normal configuration
- Each followed by a QRS complex

PR interval

- Prolonged
- More than 0.20 second (see shaded area on strip)
- Constant

QRS complex

- Within normal limits (0.08 second or less) if conduction delay occurs in AV node
- If more than 0.12 second, conduction delay may be in His-Purkinje system

T wave

- Normal size
- Normal configuration
- May be abnormal if QRS complex is prolonged

QT interval

- Within normal limits

First-degree AV block *(continued)*

What causes it

- Degenerative (age-related) changes in heart
- Drugs
 - Beta-adrenergic blockers
 - Calcium channel blockers
 - Digoxin
- MI
- Myocardial ischemia
- Myocarditis

What to look for

- Normal or slow pulse rate
- Regular rhythm
- Usually no symptoms
- Usually no significant effect on CO
- Increased interval between S_1 and S_2 heard on cardiac auscultation if PR interval is extremely long

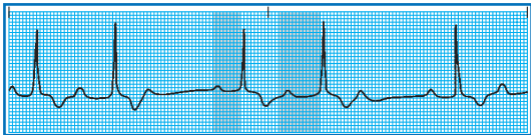
What to do

- Monitor patient's cardiac rhythm to detect progression to more serious heart block.
- Give digoxin, calcium channel blockers, and beta-adrenergic blockers cautiously.

How it's treated

- Identification and correction of underlying cause

Type I second-degree AV block



Rhythm

- Atrial: Regular
- Ventricular: Irregular

Rate

- Atrial rate exceeds ventricular rate because of nonconducted beats
- Both rates usually within normal limits

P wave

- Normal size
- Normal configuration
- Each followed by a QRS complex except blocked P wave

PR interval

- Progressively longer (see shaded areas on strip) with each cycle until a P wave appears without a QRS complex
- Commonly described as “long, longer, dropped”
- Slight variation in delay from cycle to cycle

- After the nonconducted beat, shorter than the interval preceding it

QRS complex

- Within normal limits
- Periodically absent

T wave

- Normal size
- Normal configuration
- Deflection may be opposite that of the QRS complex

QT interval

- Usually within normal limits

Other

- Wenckebach pattern of grouped beats (footprints of Wenckebach)
- PR interval gets progressively longer and R-R interval shortens until a P wave appears without a QRS complex; cycle then repeats

Type I second-degree AV block (continued)

What causes it

- CAD
- Drugs
 - Beta-adrenergic blockers
 - Calcium channel blockers
 - Digoxin
- Increased parasympathetic tone
- Inferior-wall MI
- Rheumatic fever

What to look for

- Usually no symptoms
- Evidence of decreased CO (hypotension, light-headedness)
- Pronounced signs and symptoms if ventricular rate is slow

What to do

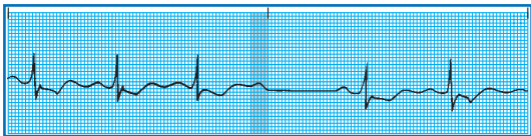
- Monitor cardiac rhythm for progression of degree of block.

- Assess patient's tolerance of rhythm.
- Observe for signs and symptoms of decreased CO.
- Evaluate patient for possible causes.
- Teach patient about temporary pacemaker, if indicated.

How it's treated

- Identification and treatment of underlying cause
- Atropine (use cautiously if patient is having an MI; atropine can worsen ischemia)
- Transcutaneous pacing, if needed, until the arrhythmia resolves

Type II second-degree AV block



Rhythm

- Atrial: Regular
- Ventricular: Irregular
- Pauses correspond to dropped beat
- Irregular when block is intermittent or conduction ratio is variable
- Regular when conduction ratio is constant, such as 2:1 or 3:1

Rate

- Atrial exceeds ventricular
- Both may be within normal limits

P wave

- Normal size
- Normal configuration
- Some not followed by a QRS complex

PR interval

- Usually within normal limits but may be prolonged
- Constant for conducted beats
- May be shortened after a nonconducted beat

QRS complex

- Within normal limits or narrow if block occurs at bundle of His
- Widened and similar to BBB if block occurs at bundle branches
- Periodically absent

T wave

- Normal size
- Normal configuration

QT interval

- Within normal limits

Other

- PR and R-R intervals don't vary before a dropped beat (see shaded area on strip), so no warning occurs
- R-R interval that contains nonconducted P wave equals two normal R-R intervals
- Must be a complete block in one bundle branch and intermittent interruption in conduction in the other bundle for a dropped beat to occur

Type II second-degree AV block (continued)

What causes it

- Anterior-wall MI
- Degenerative changes in conduction system
- Organic heart disease
- Severe CAD

What to look for

- Usually no symptoms as long as CO is adequate
- Evidence of decreased CO (as dropped beats increase)
 - Chest pain
 - Dyspnea
 - Fatigue
 - Light-headedness
- Hypotension
- Slow pulse
- Regular or irregular rhythm

What to do

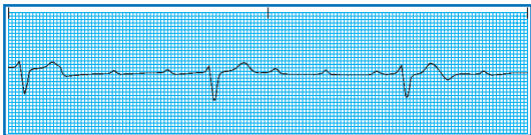
- Observe cardiac rhythm for progression to more severe block.
- Evaluate patient for correctable causes (such as ischemia).

- Administer oxygen.
- Restrict patient to bedrest.
- If patient has no serious signs and symptoms:
 - monitor patient continuously, keeping transcutaneous pacemaker attached to patient or in room.
 - prepare patient for transvenous pacemaker insertion.
- Teach patient and family about pacemakers, if indicated.

How it's treated

- Transcutaneous pacing initiated quickly when indicated and I.V. dopamine infusion, epinephrine, or combination of these drugs
- A transcutaneous pacemaker (for serious signs and symptoms) until a permanent pacemaker is placed

Third-degree AV block



Rhythm

- Atrial: Regular
- Ventricular: Regular

Rate

- Atrial: 60 to 100 beats/minute (atria act independently under control of SA node)
- Ventricular: Usually 40 to 60 beats/minute in an intra-nodal block (a junctional escape rhythm)
- Ventricular: Usually less than 40 beats/minute in infranodal block (a ventricular escape rhythm)

P wave

- Normal size
- Normal configuration
- May be buried in QRS complex or T wave

PR interval

- Not measurable

QRS complex

- Configuration depends on location of escape mechanism and origin of ventricular depolarization
- Appears normal if the block is at the level of the AV node or bundle of His
- Widened if the block is at the level of the bundle branches

T wave

- Normal size
- Normal configuration
- May be abnormal if QRS complex originates in ventricle

QT interval

- Within normal limits

Other

- Atria and ventricles are depolarized from different pacemaker sites and beat independently of each other
- P waves occur without QRS complexes

Third-degree AV block *(continued)*

What causes it

At level of AV node

- AV node damage
- Increased parasympathetic tone
- Inferior-wall MI
- Toxic effects of drugs (digoxin, propranolol)

At infranodal level

- Extensive anterior MI

What to look for

- Possibly no symptoms except exercise intolerance and unexplained fatigue
- Decreased CO from loss of AV synchrony and resulting loss of atrial kick
- Changes in level of consciousness and mental status
- Chest pain
- Diaphoresis
- Dyspnea
- Hypotension
- Light-headedness
- Pallor
- Severe fatigue
- Slow peripheral pulse rate

What to do

- Ensure patent I.V. line.
- Administer oxygen.
- Assess patient for correctable causes of arrhythmia (drugs, myocardial ischemia).
- Minimize patient's activity level.
- Restrict patient to bed rest.

How it's treated

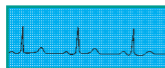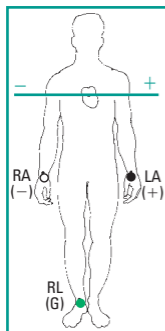
- For patient with serious signs and symptoms, immediate treatment, including:
 - transcutaneous pacing (most effective)
 - I.V. dopamine infusion, epinephrine, or combination (for short-term use in emergencies)
- Atropine contraindicated, especially when accompanied by wide-complex ventricular escape beats
- Permanent pacemaker

Limb lead placement

Proper lead placement is critical for accurate recording of cardiac rhythms. These drawings show correct electrode placement for the six limb leads. RA stands for right arm; LA, left arm; RL, right leg; and LL, left leg. A plus sign (+) indicates a positive pole, a minus sign (-) indicates a negative pole, and G indicates a ground. Below each drawing is a sample ECG strip for that lead.

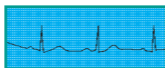
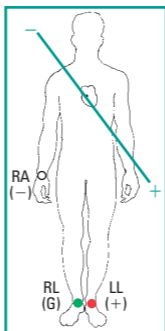
Lead I

Connects the right arm (negative pole) with the left arm (positive pole).



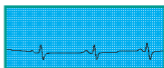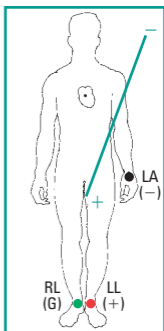
Lead II

Connects the right arm (negative pole) with the left leg (positive pole).



Lead III

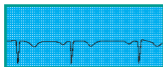
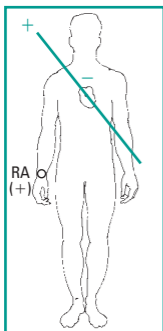
Connects the left arm (negative pole) with the left leg (positive pole).



Limb lead placement (continued)

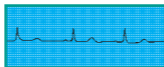
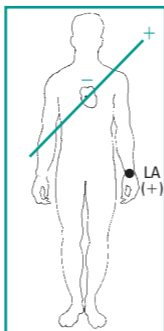
Lead aV_R

Connects the right arm (positive pole) with the heart (negative pole).



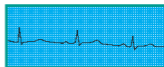
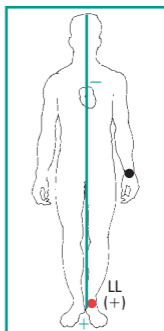
Lead aV_L

Connects the left arm (positive pole) with the heart (negative pole).



Lead aV_F

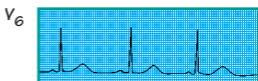
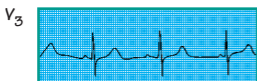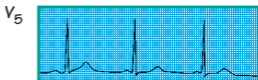
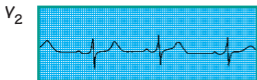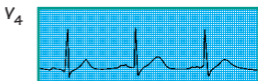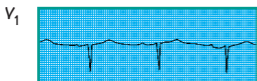
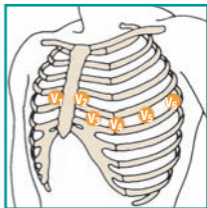
Connects the left leg (positive pole) with the heart (negative pole).



Precordial lead placement

To record a 12-lead ECG, place electrodes on the patient's arms and legs (with the ground lead on the patient's right leg). The three standard limb leads (I, II, and III) and the three augmented leads (aV_R , aV_L , and aV_F) are recorded using these electrodes. Then, to record the precordial chest leads, place electrodes as follows:

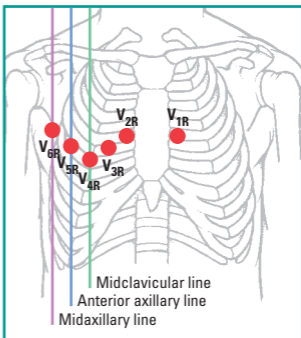
- V_1 Fourth ICS, right sternal border
- V_2 Fourth ICS, left sternal border
- V_3 Midway between V_2 and V_4
- V_4 Fifth ICS, left midclavicular line
- V_5 Fifth ICS, left anterior axillary line
- V_6 Fifth ICS, left midaxillary line



Right precordial lead placement

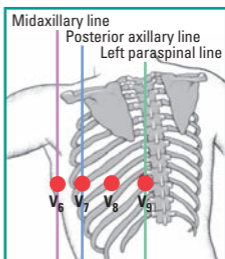
To record the right precordial chest leads, place the electrodes as follows:

- V_{1R}** Fourth ICS, left sternal border
- V_{2R}** Fourth ICS, right sternal border
- V_{3R}** Halfway between V_{2R} and V_{4R}
- V_{4R}** Fifth ICS, right midclavicular line
- V_{5R}** Fifth ICS, right anterior axillary line
- V_{6R}** Fifth ICS, right midaxillary line



Posterior lead electrode placement

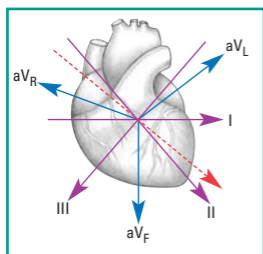
To ensure an accurate ECG reading, make sure the posterior electrodes V₇, V₈, and V₉ are placed at the same level horizontally as the V₆ lead at the fifth intercostal space. Place lead V₇ at the posterior axillary line, lead V₉ at the paraspinal line, and lead V₈ halfway between leads V₇ and V₉.



Electrical activity and the 12-lead ECG

Each of the leads on a 12-lead ECG views the heart from a different angle. These illustrations show the direction of electrical activity (depolarization) monitored by each lead and the 12 views of the heart.

Views reflected on a 12-lead ECG



Lead

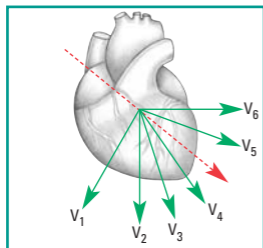
View of the heart

Limb leads (bipolar)

I	Lateral wall
II	Inferior wall
III	Inferior wall

Augmented limb leads (unipolar)

aV _R	No specific view
aV _L	Lateral wall
aV _F	Inferior wall



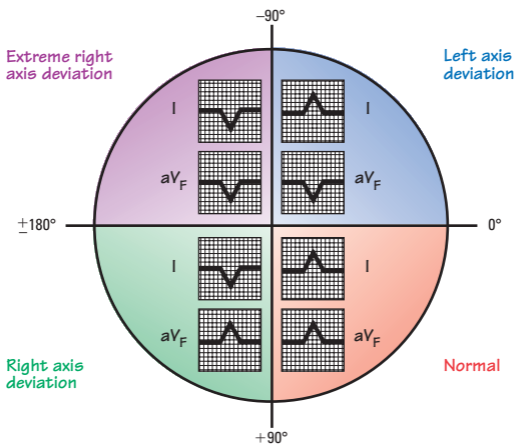
Precordial, or chest, leads (unipolar)

V ₁	Septal wall
V ₂	Septal wall
V ₃	Anterior wall
V ₄	Anterior wall
V ₅	Lateral wall
V ₆	Lateral wall

Electrical axis determination: Quadrant method

This chart will help you quickly determine the direction of a patient's electrical axis. Observe the deflections of the QRS complexes in leads I and aV_F. Lead I indicates whether impulses are moving to the right or left, and lead aV_F indicates whether they're moving up or down. Then check the chart to determine whether the patient's axis is normal or has a left, right, or extreme right deviation.

- Normal axis: QRS-complex deflection is positive or upright in both leads.
- Left axis deviation: Lead I is upright and lead aV_F points down.
- Right axis deviation: Lead I points down and lead aV_F is upright.
- Extreme right axis deviation: Both waves point down.

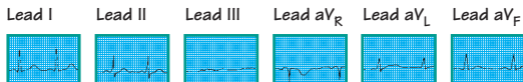


Electrical axis determination: Degree method

The degree method provides a more precise measurement of the electrical axis. It allows you to identify a patient's electrical axis by degrees on the hexaxial system, not just by quadrant. It also allows you to determine the axis even if the QRS complex isn't clearly positive or negative in leads I and aV_F . To use this method, take these steps.

Step 1

Identify the limb lead with the smallest QRS complex or the equiphasic QRS complex. In this example, it's lead III.

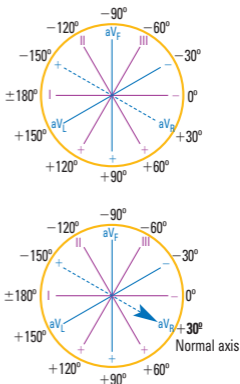


Step 2

Locate the axis for lead III on the hexaxial diagram. Then find the axis perpendicular to it, which is the axis for lead aV_R .

Step 3

Examine the QRS complex in lead aV_R , noting whether the deflection is positive or negative. As you can see, the QRS complex for this lead is negative, indicating that the current is moving toward the negative pole of aV_R , which is in the right lower quadrant at $+30^\circ$ on the hexaxial diagram. So the electrical axis here is normal at $+30^\circ$.



Causes of axis deviation

This list covers common causes of right and left axis deviation.

Left

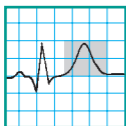
- Normal variation
- Inferior wall MI
- Left anterior hemiblock
- Wolff-Parkinson-White syndrome
- Mechanical shifts (ascites, pregnancy, tumors)
- Left bundle-branch block
- Left ventricular hypertrophy
- Aging

Right

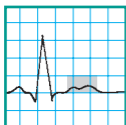
- Normal variation
- Lateral wall MI
- Left posterior hemiblock
- Right bundle-branch block
- Emphysema
- Right ventricular hypertrophy

ECG changes in angina

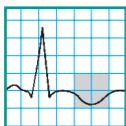
These are some classic ECG changes involving the T wave and ST segment that you may see when monitoring a patient with angina.



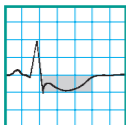
Peaked T wave



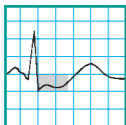
Flattened T wave



T-wave inversion



ST-segment depression with T-wave inversion

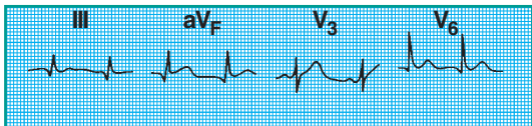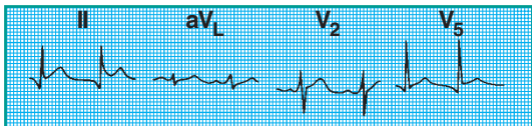
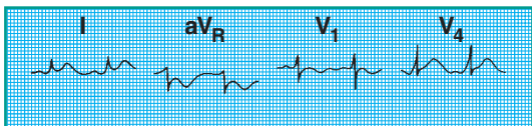


ST-segment depression without T-wave inversion

Pericarditis

ECG changes in acute pericarditis evolve through two stages:

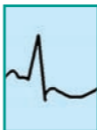- Stage 1—Diffuse ST-segment elevations of 1 to 2 mm in most limb leads and most precordial leads reflect the inflammatory process. Upright T waves appear in most leads. The ST-segment and T-wave changes are typically seen in leads I, II, III, aV_R, aV_F, and V₂ through V₆.
- Stage 2—As pericarditis resolves, the ST-segment elevation and accompanying T-wave inversion resolves in most leads.



Stages of myocardial ischemia, injury, and infarct

Ischemia

Ischemia is the first stage and indicates that blood flow and oxygen demand are out of balance. It can be resolved by improving flow or reducing oxygen needs. ECG changes indicate ST-segment depression or T wave changes.

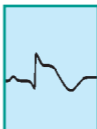

Myocardial ischemia

- T-wave inversion
- ST-depression

Injury

The second stage, injury, occurs when the ischemia is prolonged enough to damage the area of the heart. ECG changes usually reveal ST-segment elevation (usually in two or more contiguous leads).



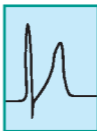
Myocardial injury

- ST-segment elevation
- T-wave inversion

Infarct

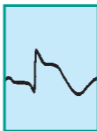
Infarct is the third stage and occurs with actual death of myocardial cells. Scar tissue eventually replaces the dead tissue, and the damage caused is irreversible.

In the earliest stage of an MI, hyperacute or very tall T waves may be seen on the ECG. Within hours, the T waves become inverted and ST-segment elevation occurs in the leads facing the area of damage. The pathologic Q wave is the last change to occur in the evolution of an MI and is the only permanent ECG evidence of myocardial necrosis.



Myocardial infarction

- Hyperacute T waves (earliest stage)



- ST-segment elevation
- T-wave inversion
- Pathologic Q waves
 - in 90% of ST-segment elevation MI
 - in 25% non-ST-segment elevation MI

Locating myocardial damage

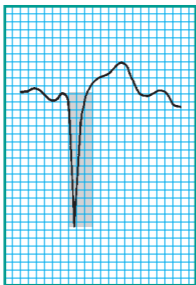
After you've noted characteristic lead changes in an acute MI, use this table to identify the areas of damage. Match the lead changes (ST elevation, abnormal Q waves) in the second column with the affected wall in the first column and the artery involved in the third column. The fourth column shows reciprocal lead changes.

Wall affected	Leads	Artery involved	Reciprocal changes
Anterior	V ₂ , V ₃ , V ₄	Left coronary artery, left anterior descending (LAD)	II, III, aV _F
Anterolateral	I, aV _L , V ₃ , V ₄ , V ₅ , V ₆	LAD and diagonal branches, circumflex and marginal branches	II, III, aV _F
Anteroseptal	V ₁ , V ₂ , V ₃ , V ₄	LAD	None
Inferior	II, III, aV _F	Right coronary artery (RCA)	I, aV _L
Lateral	I, aV _L , V ₅ , V ₆	Circumflex branch of left coronary artery	II, III, aV _F
Posterior	V ₈ , V ₉	RCA or circumflex	V ₁ , V ₂ , V ₃ , V ₄ (R greater than S in V ₁ and V ₂ , ST-segment depression, elevated T wave)
Right ventricular	V _{4R} , V _{5R} , V _{6R}	RCA	None

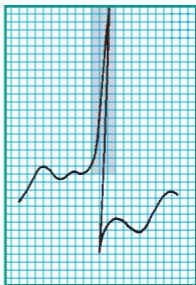
Left ventricular hypertrophy

Left ventricular hypertrophy can lead to heart failure or MI. The rhythm strips shown here illustrate key ECG changes of left ventricular hypertrophy as they occur in selected leads: a large S wave (shaded area in left strip) in V_1 and a large R wave (shaded area in right strip) in V_5 . If the depth (in mm) of the S wave in V_1 added to the height (in mm) of the R wave in V_5 exceeds 35 mm, then the patient has left ventricular hypertrophy.

Lead V_1



Lead V_5



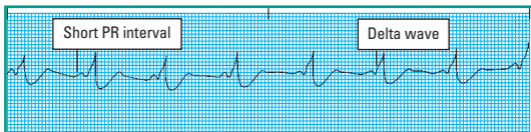
Wolff-Parkinson-White syndrome

Electrical impulses don't always follow normal conduction pathways in the heart. In WPW syndrome, electrical impulses enter the ventricles from the atria through an accessory pathway that bypasses the AV junction.

WPW syndrome is clinically significant because the accessory pathway — in this case, Kent's bundle — may result in paroxysmal tachyarrhythmias by reentry and rapid conduction mechanisms.

What happens

- A delta wave occurs at the beginning of the QRS complex, usually causing a distinctive slurring or hump in its initial slope.
- On a 12-lead ECG, the delta wave will be most pronounced in the leads looking at the part of the heart where the accessory pathway is located.
- The delta wave shortens the PR interval in WPW syndrome.



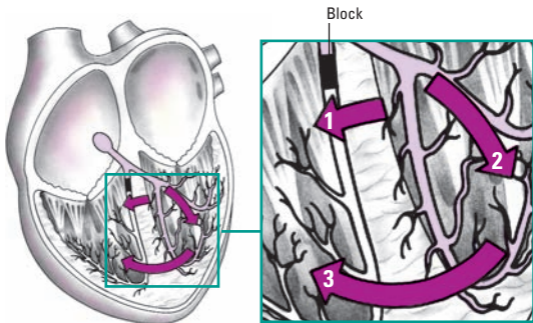
Understanding RBBB

In RBBB, the initial impulse activates the interventricular septum from left to right, just as in normal activation (arrow 1). Next, the left bundle branch activates the left ventricle (arrow 2). The impulse then crosses the interventricular septum to activate the right ventricle (arrow 3).

In this disorder, the QRS complex exceeds 0.12 second and has a different configuration, sometimes resembling rabbit ears or the letter "M." Septal depolarization isn't affected in lead V_1 , so the initial small R wave remains.

The R wave is followed by an S wave, which represents left ventricular depolarization, and a tall R wave (called *R prime*, or *R'*), which represents late right ventricular depolarization. The T wave is negative in this lead; however, the negative deflection is called a *secondary T-wave change* and isn't clinically significant.

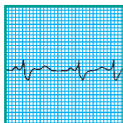
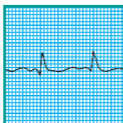
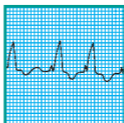
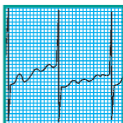
The opposite occurs in lead V_6 . A small Q wave is followed by depolarization of the left ventricle, which produces a tall R wave. Depolarization of the right ventricle then causes a broad S wave. In lead V_6 , the T wave should be positive.



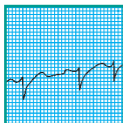
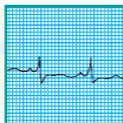
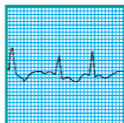
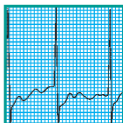
Recognizing RBBB

This 12-lead ECG shows the characteristic changes of RBBB. In lead V_1 , note the rsR' pattern and T-wave inversion. In lead V_6 , note the widened S wave and the upright T wave. Also note the prolonged QRS complexes.

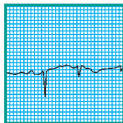
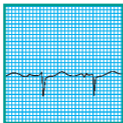
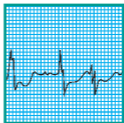
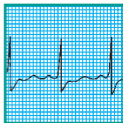
Lead I

Lead aV_R Lead V_1 Lead V_4 

Lead II

Lead aV_L Lead V_2 Lead V_5 

Lead III

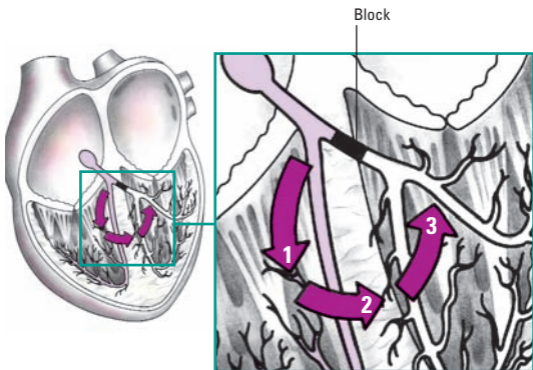
Lead aV_F Lead V_3 Lead V_6 

Understanding LBBB

In LBBB, an impulse first travels down the right bundle branch (arrow 1). Then it activates the interventricular septum from right to left (arrow 2) ventricle, the opposite of normal activation. Finally, the impulse activates the left ventricle (arrow 3).

On an ECG, the QRS complex exceeds 0.12 second because the ventricles are activated sequentially, not simultaneously. As the wave of depolarization spreads from the right ventricle to the left, a wide S wave appears in lead V_1 with a positive T wave. The S wave may be preceded by a Q wave or a small R wave.

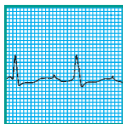
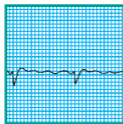
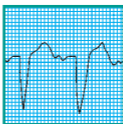
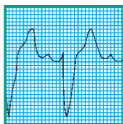
In lead V_6 , no initial Q wave occurs. A tall, notched R wave, or a slurred one, appears as the impulse spreads from right to left. This initial positive deflection is a sign of LBBB. The T wave is negative.



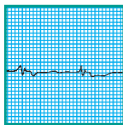
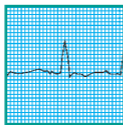
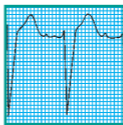
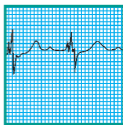
Recognizing LBBB

This 12-lead ECG shows characteristic changes of LBBB. All leads have prolonged QRS complexes. In lead V_1 , note the QS wave pattern. In lead V_6 , note the slurred R wave and T-wave inversion. The elevated ST segments and upright T waves in leads V_1 and V_4 are also common in this condition.

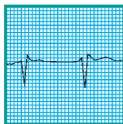
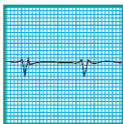
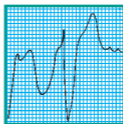
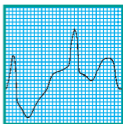
Lead I

Lead aV_R Lead V_1 Lead V_4 

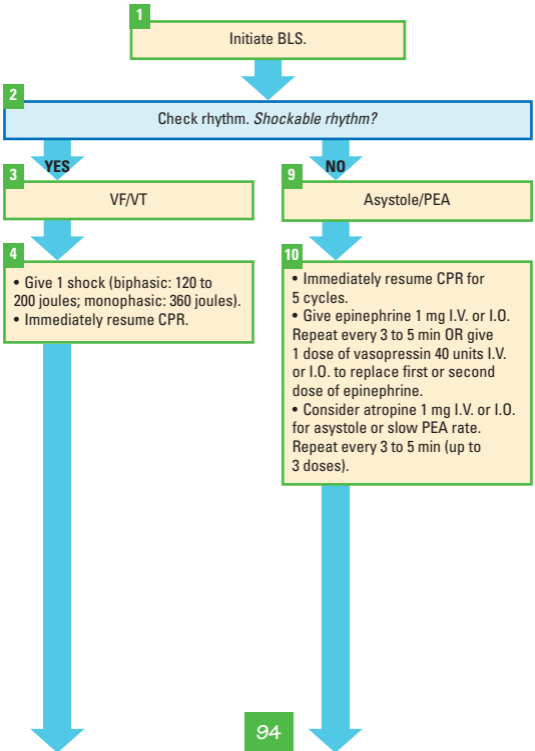
Lead II

Lead aV_L Lead V_2 Lead V_5 

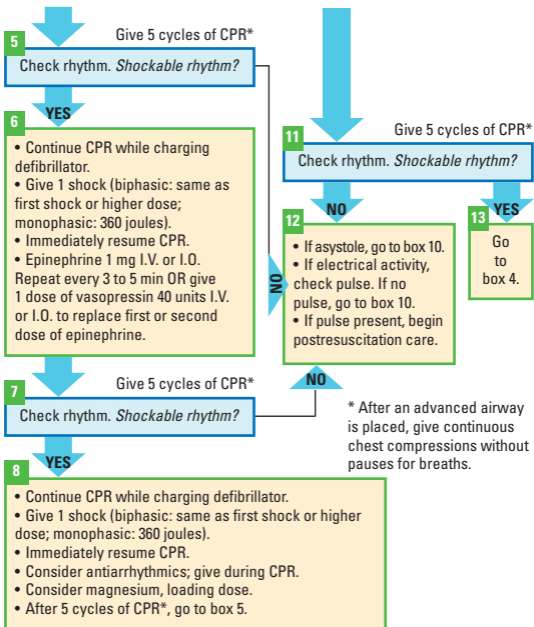
Lead III

Lead aV_F Lead V_3 Lead V_6 

Pulseless arrest algorithm



Pulseless arrest algorithm (continued)



Reprinted with permission. "2005 American Heart Association Guidelines for Cardiopulmonary Resuscitation and Emergency Cardiovascular Care," *Circulation* 2005; 112 (suppl IV). © 2005, American Heart Association.

Tachycardia algorithm

1

Tachycardia with pulses

2

- Assess and support ABCs as needed.
- Give oxygen.
- Monitor ECG (identify rhythm), blood pressure, oximetry.
- Identify and treat reversible causes.

4

Perform immediate synchronized cardioversion

- Establish I.V. access and give sedation if patient is conscious; do not delay cardioversion.
- Consider expert consultation.
- If pulseless arrest develops, see pulseless arrest algorithm.

3

Symptoms persist

Is patient stable?

Unstable signs include altered mental status, ongoing chest pain, hypotension or other signs of shock.

Unstable

5

Stable

- Establish I.V. access.
 - Obtain 12-lead ECG (when available) or rhythm strip.
- Is QRS narrow?*

6

Narrow (<0.12 sec)

Narrow QRS*

Is rhythm regular?

7

Regular

- Attempt vagal maneuvers.
- Give adenosine 6 mg rapid I.V. push. If no conversion, give 12 mg rapid I.V. push; may repeat 12 mg dose once.

11

Irregular

Irregular Narrow-Complex Tachycardia

Probable atrial fibrillation or possible atrial flutter or multifocal atrial tachycardia

- Consider expert consultation.
- Control rate (diltiazem, beta blockers; use beta blockers with caution in pulmonary disease or CHF).

12

Wide (>0.12 sec)

Wide QRS*

Is rhythm regular?

Expert consultation advised.

Tachycardia algorithm (continued)

8

Does rhythm convert?

Note: Consider expert consultation.

9

Converts

If rhythm converts, probably reentry supra-ventricular tachycardia (SVT)

- Observe for recurrence.
- Treat recurrence with adenosine or longer-acting AV nodal blocking agents (such as diltiazem or beta blockers).

10 Does not convert

If rhythm does NOT convert, possible atrial flutter, ectopic atrial tachycardia, or junctional tachycardia

- Control rate (diltiazem, beta blockers; use beta blockers with caution in pulmonary disease or CHF).
- Treat underlying cause.
- Consider expert consultation.

13

Regular

If ventricular tachycardia or uncertain rhythm

- Amiodarone 150 mg I.V. over 10 min. Repeat as needed to maximum dose of 2.2 g/24 hours.
 - Prepare for elective synchronized cardioversion.
- If SVT with aberrancy**
- Give adenosine (go to box 7).

14

Irregular

If atrial fibrillation with aberrancy

- See Irregular Narrow-Complex Tachycardia (box 11).

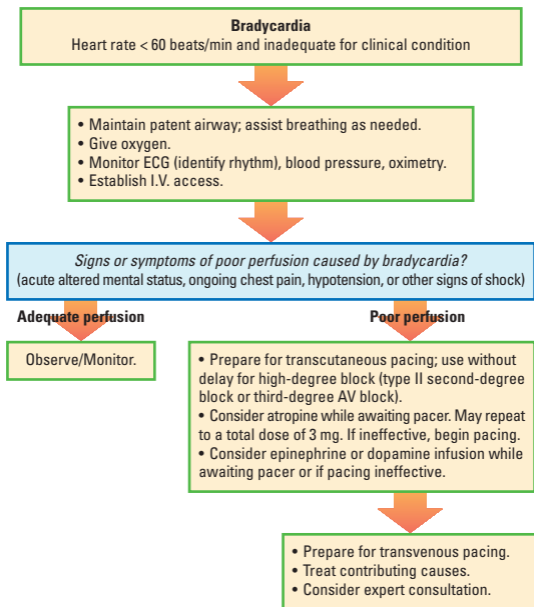
If pre-excited atrial fibrillation (AF + WPW)

- Expert consultation advised.
 - Avoid AV nodal blocking agents (adenosine, digoxin, diltiazem, verapamil).
 - Consider anti-arrhythmics (amiodarone 150 mg I.V. over 10 min).
- If recurrent polymorphic VT**
- Seek expert consultation.
- If torsades de pointes**
- Give magnesium (load with 1 to 2 g over 5 to 60 min, then infusion).

*Note: If patient becomes unstable, go to box 4.

Reprinted with permission. "2005 American Heart Association Guidelines for Cardiopulmonary Resuscitation and Emergency Cardiovascular Care," *Circulation* 2005; 112 (suppl IV). © 2005, American Heart Association.

Bradycardia algorithm



Reprinted with permission. "2005 American Heart Association Guidelines for Cardiopulmonary Resuscitation and Emergency Cardiovascular Care," *Circulation* 2005; 112 (suppl IV). © 2005, American Heart Association.

Guide to antiarrhythmic drugs

This chart details the drugs most commonly used to manage cardiac arrhythmias, including indications and special considerations for each.

Drugs	Indications	Special considerations
<i>Class IA antiarrhythmics</i>		
Disopyramide, procainamide, quinidine	<ul style="list-style-type: none"> •VT •Atrial fibrillation •Atrial flutter •PAT 	<ul style="list-style-type: none"> •Check apical pulse rate before therapy. If you note extremes in pulse rate, withhold the dose and notify the prescriber. •Use cautiously in patients with reactive airway disease such as asthma. •Monitor for ECG changes (widening QRS complexes, prolonged QT interval).
<i>Class IB antiarrhythmics</i>		
Lidocaine, mexiletine	<ul style="list-style-type: none"> •VT •VF 	<ul style="list-style-type: none"> •IB antiarrhythmics may potentiate the effects of other antiarrhythmics. •Administer I.V. infusions using an infusion pump.
<i>Class IC antiarrhythmics</i>		
Flecainide, moricizine, propafenone	<ul style="list-style-type: none"> •VT •VF •Supraventricular arrhythmias 	<ul style="list-style-type: none"> •Correct electrolyte imbalances before administration. •Monitor the patient's ECG before and after dosage adjustments. •Monitor for ECG changes (widening QRS complexes, prolonged QT interval).

(continued)

Guide to antiarrhythmic drugs (continued)

Drugs	Indications	Special considerations
<i>Class II antiarrhythmics</i>		
Acebutolol, atenolol, esmolol, propranolol	<ul style="list-style-type: none"> • Atrial flutter • Atrial fibrillation • PAT 	<ul style="list-style-type: none"> • Monitor apical HR and BP. • Abruptly stopping these drugs can exacerbate angina and precipitate MI. • Monitor for ECG changes (prolonged PR interval). • Drugs may mask common signs and symptoms of shock and hypoglycemia. • Use cautiously in patients with reactive airway disease such as asthma.
<i>Class III antiarrhythmics</i>		
Amiodarone, dofetilide, ibutilide, sotalol	<ul style="list-style-type: none"> • Life-threatening arrhythmias resistant to other antiarrhythmic drugs 	<ul style="list-style-type: none"> • Monitor BP and heart rate and rhythm for changes. • Amiodarone increases the risk of digoxin toxicity in patients also taking digoxin. • Monitor for signs of pulmonary toxicity (nonproductive cough, dyspnea, and pleuritic chest pain), thyroid dysfunction, and vision impairment in patients taking amiodarone. • Monitor for ECG changes (prolonged QT interval) in patients taking dofetilide, ibutilide, and sotalol.
<i>Class IV antiarrhythmics</i>		
Diltiazem, verapamil	<ul style="list-style-type: none"> • Supraventricular arrhythmias 	<ul style="list-style-type: none"> • Monitor heart rate and rhythm and BP carefully when initiating therapy or increasing dosage. • Calcium supplements may reduce effectiveness.

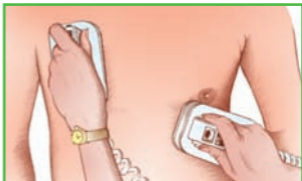
Guide to antiarrhythmic drugs (continued)

Drugs	Indications	Special considerations
<i>Miscellaneous antiarrhythmics</i>		
Adenosine	<ul style="list-style-type: none"> • PSVT 	<ul style="list-style-type: none"> • Adenosine must be administered over 1 to 2 seconds, followed by a 20-ml flush of normal saline solution. • Record rhythm strip during administration. Adenosine may cause transient asystole or heart block.
Atropine	<ul style="list-style-type: none"> • Symptomatic SB • AV block • Asystole • Bradycardic PEA 	<ul style="list-style-type: none"> • Monitor heart rate and rhythm. Use the drug cautiously in patients with myocardial ischemia. • Atropine isn't recommended for third-degree AV block or infranodal type II second-degree AV block. • In adults, avoid doses less than 0.5 mg because of the risk of paradoxical slowing of the HR.
Epinephrine	<ul style="list-style-type: none"> • Pulseless VT • VF • Asystole • PEA 	<ul style="list-style-type: none"> • Monitor heart rate and rhythm and BP carefully because the drug may cause myocardial ischemia. • Don't mix an I.V. dose with alkaline solutions. • Give drug into a large vein to prevent irritation or extravasation at site.
Vasopressin	<ul style="list-style-type: none"> • VF that's unresponsive to defibrillation 	<ul style="list-style-type: none"> • Monitor heart rate and rhythm. Use the drug cautiously in patients with myocardial ischemia. • Monitor for hypersensitivity reactions, especially urticaria, angioedema, and bronchoconstriction.

Defibrillator paddle placement

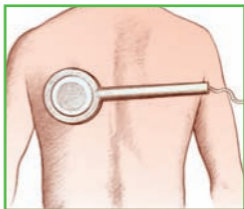
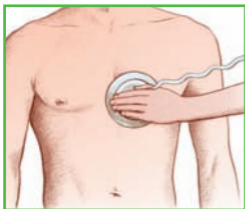
Anterolateral placement

Place one paddle to the right of the upper sternum, just below the right clavicle, and the other over the fifth or sixth intercostal space at the left anterior axillary line.



Anteroposterior placement

Place the anterior paddle directly over the heart at the precordium, to the left of the lower sternal border. Place the flat posterior paddle under the patient's body beneath the heart and just below the left scapula (but not under the vertebral column).



Safety issues with defibrillation

Precautions must be taken when defibrillating a patient with an ICD, a pacemaker, or a transdermal medication patch or a patient who's in contact with water.

Defibrillating a patient with an ICD or pacemaker

Avoid placing the defibrillator paddles or pads directly over the implanted device. Place them at least 1" (2.5 cm) away from the device.

Defibrillating a patient with a transdermal medication patch

Avoid placing the defibrillator paddles or pads directly on top of a transdermal medication patch, such as a nitroglycerin, nicotine, analgesic, or hormone replacement patch. The patch can block delivery of energy and cause a small burn to the skin. Remove the medication patch and wipe the area clean before defibrillation.

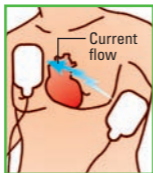
Defibrillating a patient near water

Water is a conductor of electricity and may provide a pathway for energy from the defibrillator to the rescuers treating the victim. Remove the patient from freestanding water and dry his chest before defibrillation.

Monophasic and biphasic defibrillators

Monophasic defibrillators

Monophasic defibrillators deliver a single current of electricity that travels in one direction between the two pads or paddles on the patient's chest. To be effective, a large amount of electrical current is required for monophasic defibrillation.

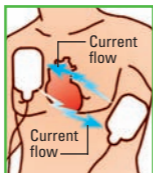


To be effective, a large amount of electrical current is required for monophasic defibrillation.

Biphasic defibrillators

Biphasic defibrillators have the same pad or paddle placement as with the monophasic defibrillator. The differ-

ence is that during biphasic defibrillation, the electrical current discharged from the pads or paddles travels in a positive direction for a specified duration and then reverses and flows in a negative direction for the remaining time of the electrical discharge.



Energy efficient

The biphasic defibrillator delivers two currents of electricity and lowers the defibrillation threshold of the heart muscle, making it possible to successfully defibrillate VF with smaller amounts of energy.

Adjustable

The biphasic defibrillator can adjust for differences in impedance or resistance of the current through the chest. This reduces the number of shocks needed to terminate VF.

Less myocardial damage

Because the biphasic defibrillator requires lower energy levels and fewer shocks, damage to the myocardial muscle is reduced. Biphasic defibrillators used at the clinically appropriate energy level may be used for defibrillation and, in the synchronized mode, for synchronized cardioversion.

Synchronized cardioversion

How it works

In synchronized cardioversion, an electric current is delivered to the heart to correct an arrhythmia. This procedure may be done electively in a stable patient with recurrent atrial fibrillation or urgently in an unstable patient with such arrhythmias as PSVT, atrial flutter, atrial fibrillation, and VT with a pulse.

Compared with defibrillation, synchronized cardioversion uses much lower energy levels and is synchronized to deliver an electric charge to the myocardium on the peak R wave.

What it does

The procedure causes immediate depolarization, interrupting reentry circuits (abnormal impulse conduction that occurs when cardiac tissue is activated two or more times, causing reentry arrhythmias) and allowing the SA node to resume control.

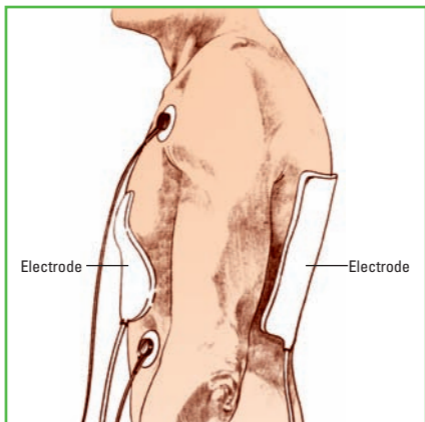
Synchronizing the electric charge with the R wave ensures that the current won't be delivered on the vulnerable T wave and disrupts repolarization. This reduces the risk that the current will strike during the relative refractory period of a cardiac cycle and induce VF.

Transcutaneous pacemaker

Transcutaneous pacing, also referred to as *external* or *noninvasive pacing*, involves the delivery of electrical impulses through externally applied cutaneous electrodes. The electrical impulses are conducted through an intact chest wall using skin electrodes placed in either anterior-posterior or sternal-apex positions. (An anterior-posterior placement is shown here.)

When to use it

Transcutaneous pacing is the pacing method of choice in emergency situations because it's the least invasive technique and it can be instituted quickly.



Placing a permanent pacemaker

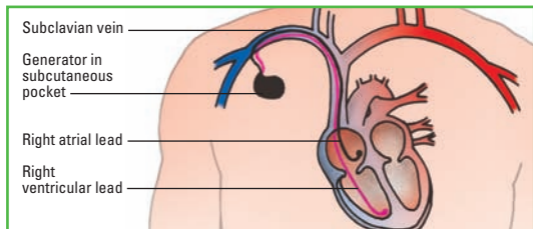
Implanting a pacemaker is a simple surgical procedure performed with local anesthesia and moderate sedation. To implant an endocardial pacemaker, the surgeon usually selects a transvenous route and begins lead placement by inserting a catheter percutaneously or by venous cutdown. Using fluoroscopic guidance, the surgeon then threads the catheter through the vein until the tip reaches the endocardium.

Lead placement

For lead placement in the atrium, the tip must lodge in the right atrium or coronary sinus, as shown below. For placement in the ventricle, it must lodge in the right ventricular apex in one of the interior muscular ridges, or trabeculae (as shown below).

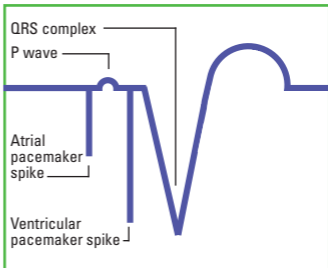
Implanting the generator

When the lead is in proper position, the surgeon secures the pulse generator in a subcutaneous pocket of tissue just below the patient's clavicle. Changing the generator's battery or microchip circuitry requires only a shallow incision over the site and a quick exchange of components.



Pacemaker spikes

Pacemaker impulses—the stimuli that travel from the pacemaker to the heart—appear as spikes on an ECG tracing. Whether large or small, pacemaker spikes appear above or below the isoelectric line. This illustration shows an atrial pacemaker spike and a ventricular pacemaker spike.



Understanding pacemaker codes

A permanent pacemaker's three-letter (or sometimes five-letter) code simply refers to how it's programmed.

First letter

(chamber that's paced)

- A** atrium
- V** ventricle
- D** dual (both chambers)
- O** not applicable

Second letter

(chamber that's sensed)

- A** atrium
- V** ventricle
- D** dual (both chambers)
- O** not applicable

Third letter

(pulse generator's response)

- I** inhibited
- T** triggered
- D** dual (inhibited and triggered)
- O** not applicable

Fourth letter

(pacemaker's programmability)

- P** basic functions programmable
- M** multiple programmable parameters
- C** communicating functions such as telemetry
- R** rate responsiveness
- N** none

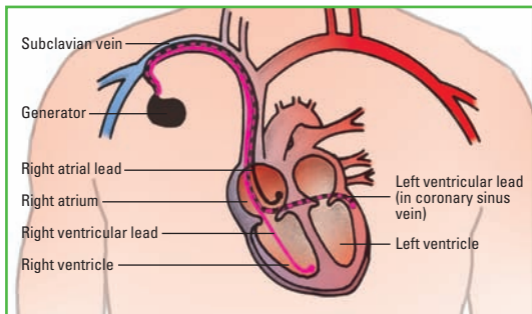
Fifth letter

(pacemaker's response to tachycardia)

- P** pacing ability
- S** shock
- D** dual ability to shock and pace
- O** none

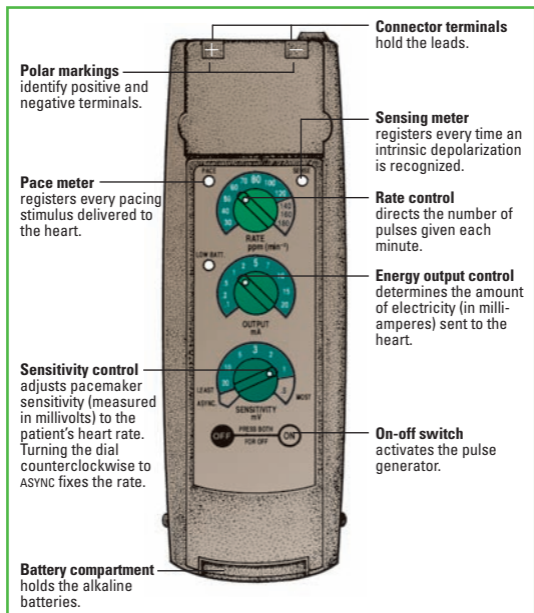
Biventricular lead placement

A biventricular pacemaker uses three leads: one to pace the right atrium, one to pace the right ventricle, and one to pace the left ventricle. The left ventricular lead is placed in the coronary sinus. Both ventricles are paced at the same time, causing them to contract simultaneously, which improves CO.



Temporary pulse generator

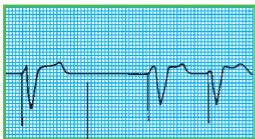
The settings on a temporary pulse generator may be changed in various ways to meet the patient's specific needs. This illustration shows a single-chamber temporary pulse generator and gives brief descriptions of its various parts.



Temporary pacemaker malfunctions

Failure to pace

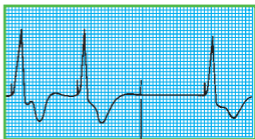
ECG shows no pacemaker activity when activity should be present.



Pacemaker spike should appear here

Failure to capture

ECG shows pacemaker spikes but the heart isn't responding.



There's a pacemaker spike but no response from the heart

Nursing interventions

- Check connections to cable and position of pacing electrode in patient (by X-ray).
- If pulse generator is on but indicators aren't flashing, change battery. If that doesn't help, change pulse generator.
- Adjust the sensitivity setting.

Nursing interventions

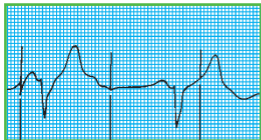
- If patient's condition has changed, notify doctor and ask for new settings.
- If pacemaker settings are altered, return them to their correct positions.
- If heart isn't responding, check all connections; increase milliamperes slowly (according to policy or doctor's order); turn patient on his left side, then on his right; and schedule an anteroposterior or lateral chest X-ray to determine position of electrode.

(continued)

Temporary pacemaker malfunctions (continued)

Failure to sense intrinsic beats (undersensing)

ECG shows pacemaker spikes anywhere in the cycle (the pacemaker fires, but at the wrong times or for the wrong reasons).



The pacemaker fires anywhere in the cycle

Nursing interventions

- If the pacemaker is undersensing, turn the sensitivity control completely to the right.
- If the pacemaker isn't functioning correctly, change the battery or pulse generator.
- Remove items in room causing electromechanical interference (such as electric razors, radios, and cautery devices). Check ground wires on the bed and other equipment for damage. Unplug each piece and see if interference stops. When you locate the cause, ask a staff engineer to check it.
- If the pacemaker is still firing on the T wave, notify the doctor and turn off the pacemaker. Have atropine available in case HR drops. Call a code and institute CPR if needed.

ICD review

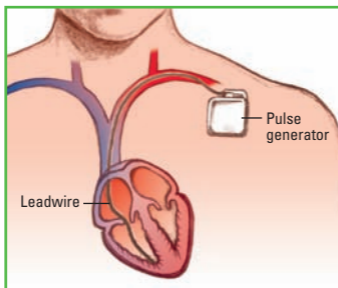
An ICD has a programmable pulse generator and lead system that monitors the heart's activity, detects ventricular arrhythmias and other tachyarrhythmias, and responds with appropriate therapies.

What it does

The range of therapies includes antitachycardia and antibradycardia pacing, cardioversion, and defibrillation. The ICD can also pace both the right atrium and right ventricle. Some can perform biventricular pacing. ICDs that provide therapy for atrial arrhythmias, such as atrial fibrillation, are also available.

Implanting the ICD

Implantation of an ICD is similar to that of a permanent pacemaker. The cardiologist positions the lead (or leads) transvenously in the endocardium of the right ventricle (and the right atrium, if both chambers need pacing). The lead connects to a generator box implanted in the right or left upper chest near the clavicle.



Types of ICD therapies

ICDs can deliver a range of therapies depending on the arrhythmia detected and how the device is programmed. Some ICDs can also detect and treat atrial arrhythmias or provide biventricular pacing. Therapies include antitachycardia pacing, cardioversion, defibrillation, and bradycardia pacing.

Therapy	Description
Antitachycardia pacing	A series of small, rapid, electrical pacing pulses are used to interrupt VT and return the heart to its normal rhythm.
Cardioversion	A low- or high-energy shock (up to 35 joules) is timed to the R wave to terminate VT and return the heart to its normal rhythm.
Defibrillation	A high-energy shock (up to 35 joules) to the heart is used to terminate VF and return the heart to its normal rhythm.
Bradycardia pacing	Electrical pacing pulses are used when the heart's natural electrical signals are too slow. ICD systems can pace one chamber (VVI pacing) of the heart at a preset rate or sense and pace both chambers (DDD pacing).

Managing an ICD

Device

- Know the device and how it's programmed, including:
 - type and model of ICD
 - status of the device (on or off)
 - detection rates
 - types of therapies that will be delivered and when.

Appropriateness

- Evaluate the appropriateness of ICD shocks, including:
 - number of isolated and multiple shocks
 - situation and activity related to shocks
 - patient symptoms
 - ECG rhythm
 - drugs taken.

Shocks

- Shocks may not occur despite VT or VF under certain circumstances, such as:
 - if the HR is less than the detection rate
 - if there's a lead or circuitry problem
 - if therapy is suspended or turned off
 - if the battery is depleted.
- Shocks can occur without VT or VF under certain circumstances, such as:
 - when the rate in ST ventures into the VT zone
 - when noise is detected on the sensing lead (from electromagnetic interference or lead dysfunction)
 - when the patient develops atrial fibrillation.
- Multiple shocks may occur in certain circumstances, such as:
 - when the patient has persistent or recurrent VT or VF
 - when the device malfunctions.

(continued)

Managing an ICD (continued)

- Multiple shocks indicate a medical emergency, and the patient may require adjunct treatment, such as:
 - CPR
 - external defibrillation
 - drugs, such as amiodarone, lidocaine, procainamide
 - suspension of tachyarrhythmia therapy by magnet application or reprogramming of device.

Problems

- If cardiac arrest occurs in a patient with an ICD, CPR and ACLS should be used immediately.
- If the patient needs external defibrillation, take these steps:
 - Position the paddles as far from the device as possible or use anterior-posterior position.
 - Anticipate that defibrillation will result in “power on reset” and reversion to nominal settings.
 - Programming of the device should be verified with the programmer.
- Look for evidence of problems, including:
 - decreased CO (hypotension, chest pain, dyspnea, syncope)
 - infection
 - pneumothorax
 - misplaced electrode (abnormal electrical stimulation occurring in synchrony with the pacemaker, such as pectoral muscle twitching)
 - stimulation of diaphragm (hiccups)
 - cardiac tamponade.

Selected references

- American Heart Association. *Handbook of Emergency Cardiovascular Care for Healthcare Providers*. Dallas: American Heart Association, 2005.
- Assessment Made Incredibly Easy*, 4th ed. Philadelphia: Lippincott Williams & Wilkins, 2008.
- Cardiovascular Care Made Incredibly Visual*. Philadelphia: Lippincott Williams & Wilkins, 2007.
- ECG Interpretation Made Incredibly Easy*, 4th ed. Philadelphia: Lippincott Williams & Wilkins, 2008.
- Fugate, J.H. "Pharmacologic Management of Cardiac Emergencies," *Journal of Infusion Nursing* 29(3):147-50, May-June 2006.
- Lippincott's Nursing Procedures*, 5th ed. Philadelphia: Lippincott Williams & Wilkins, 2009.
- Moses, H.W., and Mullin, J.C. *A Practical Guide to Cardiac Pacing*, 6th ed. Philadelphia: Lippincott Williams & Wilkins, 2007.
- Nursing2009 Drug Handbook*, 29th ed. Philadelphia: Lippincott Williams & Wilkins, 2009.
- Nursing Know-How: Interpreting ECGs*. Philadelphia: Lippincott Williams & Wilkins, 2008.
- Tsiperfal, A., et al. "What Is Drug-Induced Long QT and What Is a Potential Clinical Consequence?" *Progress in Cardiovascular Nursing* 21(2):104-5, Spring 2006.
- Wysocki, L. "ST Segment Changes Clue You In to Injury Location," *RN* 69(9):49, September 2006.

Index

- Abbreviations, vi
- Accelerated junctional rhythm, 46-47
- Accelerated idioventricular rhythm, 56-57
- Angina, ECG changes in, 84
- Antiarrhythmic drugs, 99-101
- Ashman's phenomenon, 38-39
- Asystole, 64-65
- Atrial fibrillation, 36-37
- Atrial flutter, 34-35
- Atrial tachycardia, 30-33
- Bradycardia
 - algorithm for, 98
 - in children, 13
- Cardiac conduction system, 4
- Cardioversion, synchronized, 105
- Coronary vessels, 2-3
- Defibrillators
 - paddle placement, 102
 - safety issues with, 103
 - types of, 104
- ECG
 - evaluation, 9
 - grid, 4
 - normal, 8
 - QTc interval normals, 9
- Einthoven's triangle, 5
- Electrical axis
 - determination of, 81-82
 - deviation of, 83
- Electrolyte imbalances, ECG and, 14
- First-degree AV block, 68-69
- Heart location, 1
- Heart rate
 - calculating, 12
 - in children, 13
- ICD, 113
 - managing, 115-116
 - therapies delivered by, 114
- Idioventricular rhythm, 54-55
- Junctional rhythm, 44-45
- Junctional tachycardia, 48-49
- LBBB, 92-93
- Leads
 - augmented, 6
 - best monitoring, ii
 - biventricular, placement of, 109
 - cardiac monitoring, positioning, 7
 - limb, placement of, 76-77
 - posterior, placement of, 79
 - precordial, placement of, 78-79
- Left ventricular hypertrophy, 88
- Myocardial infarct, 86
 - locating damage in, 87
- Myocardial injury, 86
- Myocardial ischemia, 86
- Pacemaker
 - biventricular, 109
 - codes, 108
 - implanting, 107
 - malfunctions, 111-112
 - spikes, 108
 - transcutaneous, 106
- PACs, 28-29
- Pericarditis, ECG changes in, 85
- PJCs, 42-43
- Pulseless arrest algorithm, 94-95
- Pulseless electrical activity, 66-67
- PVCs, 50-53
- QTc interval, normal, 9
- RBBB, 90-91
- Rhythm strips
 - interpreting, 9
 - methods of measuring, 10
 - patterns of, 11
- SA exit block, 24-25
- Sick sinus syndrome, 26-27
- Sinus arrest, 22-23
- Sinus arrhythmia, 16-17
- Sinus bradycardia, 18-19
- Sinus rhythm, normal, 15
- Sinus tachycardia, 20-21
- Tachycardia
 - algorithm, 96-97
 - in children, 13
- Temporary pulse generator, 110
- Third-degree AV block, 74-75
- Torsades de pointes, 60-61
- 12-lead, electrical activity and, 80
- Type I second-degree AV block, 70-71
- Type II second-degree AV block, 72-73
- Ventricular fibrillation, 62-63
- Ventricular tachycardia, 58-59
- Wandering pacemaker, 40-41
- WPW syndrome, 89